Journal of the Society for Cardiovascular Angiography & Interventions xxx (xxxx) xxx

JSCAI

The official journal of the Society for Cardiovascular Angiography & Interventions

Standards and Guidelines

SCAI Expert Consensus Statement on Alternative Access for Transcatheter Aortic Valve Replacement

Matthew Sherwood, MD, MHS, FSCAI[a,*], Keith B. Allen, MD[b], Thom G. Dahle, MD, FSCAI[c], Chandan M. Devireddy, MD, FSCAI[d], Jeffrey Gaca, MD[e], Santiago Garcia, MD, FSCAI[f], Kendra J. Grubb, MD, MHA[d], Tsuyoshi Kaneko, MD[g], Chad A. Kliger, MD, FSCAI[h], Robert J. Lederman, MD[i], John C. Messenger, MD, FSCAI[j], Puja B. Parikh, MD, MPH, FSCAI[k], Marie-France Poulin, MD, FSCAI[l], Carlos Sanchez, MD, FSCAI[m], Anene Ukaigwe, MD, FSCAI[n], James J. Yun, MD[o], Paul D. Mahoney, MD, FSCAI[p]

[a] *Inova Heart and Vascular Institute, Fairfax, Virginia;* [b] *Saint Luke's Mid America Heart Institute, Kansas City, Missouri;* [c] *CentraCare Heart and Vascular Center, St. Cloud, Minnesota;* [d] *Emory University School of Medicine, Atlanta, Georgia;* [e] *Duke University Hospital, Durham, North Carolina;* [f] *The Christ Hospital Health Network, Cincinnati, Ohio;* [g] *Washington University in St. Louis, St. Louis, Missouri;* [h] *Northwell Health, New Hyde Park, New York;* [i] *Division of Intramural Research, National Heart, Lung, and Blood Institute, National Institutes of Health, Bethesda, Maryland;* [j] *University of Colorado Medicine, Aurora, Colorado;* [k] *Stony Brook University Hospital, Stony Brook, New York;* [l] *Beth Israel Deaconess Medical Center, Boston, Massachusetts;* [m] *Riverside Methodist Hospital, Columbus, Ohio;* [n] *Case Western Reserve University Hospital, Cleveland, Ohio;* [o] *Cleveland Clinic, Cleveland, Ohio;* [p] *East Carolina University, Greenville, North Carolina*

ABSTRACT

Transcatheter aortic valve replacement (TAVR) has become a widely accepted procedure for treating patients with symptomatic aortic stenosis. While transfemoral access remains the primary route due to its lower complication rates and favorable outcomes, a subset of patients have anatomical or clinical factors precluding this approach. For these patients, alternative access routes such as transaxillary, transcarotid, and transcaval provide viable options. This expert consensus statement aims to provide a comprehensive review of case selection, technical considerations, and outcomes associated with these alternative access routes in TAVR. Additionally, this document highlights the advancements in device technology and imaging guidance that have contributed to improving the safety and efficacy of alternative access TAVR. This consensus statement serves as a practical guide on best practices for interventional cardiologists, cardiothoracic surgeons, and heart teams in selecting patients and performing alternative access TAVR.

Table of Contents

Introduction 2
Methodology 2
Imaging evaluation of access 2
Consensus Statements: 2
Computed tomography angiography acquisition and analysis . 3
Axillary/subclavian approach 3
Consensus statements:. 3
Patient screening/equipment/procedure 3
Percutaneous and surgical axillary access technique 3
Postprocedural care and complications 3
Outcomes 3
Transcaval approach 4
Consensus statements 4
Patient screening, equipment, and procedure 5
Challenges and postprocedural care 5
Complications and outcomes 5
Transcarotid approach 5
Consensus statements 5
Preoperative imaging/evaluation. 5
Carotid artery exposure/intraoperative monitoring 5
Outcomes 6
Intrathoracic access: transapical and transaortic 7
Consensus statements:. 7
Transapical and transaortic access. 7

Abbreviations: CTA, computed tomography angiography; ECG, electrocardiogram; IVC, inferior vena cava; IVL, intravascular lithotripsy; PVI, peripheral vascular intervention; TAVR, transcatheter aortic valve replacement; THV, transcatheter heart valve.

Keywords: alternative access; transcarotid; transcatheter aortic valve replacement; transcaval; vascular access.

* Corresponding author: matthew.sherwood@inova.org (M. Sherwood).

https://doi.org/10.1016/j.jscai.2024.102514
Received 7 October 2024; Received in revised form 9 December 2024; Accepted 13 December 2024
2772-9303/© 2025 The Author(s). Published by Elsevier Inc. on behalf of Society for Cardiovascular Angiography & Interventions Foundation. This is an open access article under the CC BY-NC-ND license (http://creativecommons.org/licenses/by-nc-nd/4.0/).

Transapical TAVR—operative technique . . . 7
Transaortic TAVR—operative technique . . . 7
Outcomes . . . 7
Augmented transfemoral access (IVL, percutaneous balloon angioplasty, bare metal, and covered stenting) . . . 7
Comparison of nonfemoral TAVR access approaches . . . 8
Consensus Statements . . . 8
Transcarotid vs transaxillary/subclavian . . . 8
Transcaval vs transaxillary/subclavian . . . 8
Role of proctoring . . . 8
Consensus statements . . . 8
Role of physician proctoring . . . 9
Conclusions and future directions . . . 10
Declaration of competing interest . . . 10
Funding sources . . . 10
Supplementary material . . . 10
References . . . 10

Introduction

Transcatheter aortic valve replacement (TAVR) is a mainstay treatment for patients with symptomatic, severe aortic stenosis.[1] As TAVR technology and technique have improved over the past decade, the majority of TAVR procedures are performed via the femoral artery; however, there remain patients with iliofemoral arteries that are too small or diseased to safely undergo transfemoral TAVR. Alternative (nonfemoral artery) access, most commonly via transaxillary, transcarotid, or transcaval routes, remains necessary in 4.7% of TAVR procedures in the United States.[2] Transapical and transthoracic access, once common, are now seldom performed.[3]

Transaxillary arterial access can be accomplished either percutaneously or with surgical exposure to place a delivery sheath.[4] Transcarotid access uses local surgical exposure for delivery sheath access followed by repair after TAVR. Transcaval access uses percutaneous femoral vein access for introduction of the delivery sheath, followed by use of an electrified guide wire to traverse from the inferior vena cava (IVC) through the retroperitoneal space into an adjacent segment of the abdominal aorta, followed by passage of the TAVR delivery sheath.[5] After transcaval TAVR, a nitinol occluder device is implanted in the aortocaval access tract while the sheath is withdrawn. Intrathoracic (transapical or transaortic) TAVR is associated with higher morbidity and mortality than extrathoracic access.[3,6]

Possible explanations for the increased risk of alternative access approaches include patient-specific features (eg, increased medical comorbidities and more diseased/tortuous/calcific/atheromatous arteries) as well as procedure-specific factors (eg, greater procedural complexity or risk or the need for general anesthesia).

Augmented transfemoral arterial access using intravascular lithotripsy (IVL), bare metal or covered-stent implantation, and/or balloon angioplasty remains an important alternative to standard transfemoral access cases. Case selection and relative risk of this approach compared with nontransfemoral arterial access has not been well-studied.

Few guidelines are available to help operators select among alternative access options.[7,8] Current guidelines on management of valvular heart disease from the American College of Cardiology/American Heart Association make no recommendations on the specific alternative access techniques for TAVR. However, in recognition of increased patient and procedural complexity, these guidelines recommend that alternative access be performed at level I/comprehensive valve centers, while level II/primary valve centers perform only transfemoral TAVR. Similarly, the European Society of Cardiology/European Association for Cardio-Thoracic Surgery Guidelines for the Management of Valvular Heart Disease offer no specific recommendations on alternative access options and emphasize consideration of surgical aortic valve repair over TAVR in patients with poor anatomical features and vascular access.[8] In light of this gap in clinical guidelines, the Society for Cardiovascular Angiography & Interventions (SCAI) organized an expert panel to summarize available evidence and develop a consensus statement on best practices for alternative, nonfemoral access case selection for TAVR. The aim of this document was to inform clinicians on current best practices for alternative access case selection and technique and to promote improved clinical outcomes and safety in these difficult clinical cases.

Methodology

This statement has been developed according to the SCAI Standards and Guidelines Committee policies for writing group composition, disclosure, and management of relationships with industry, internal and external review, and organizational approval.[9]

The writing group was assembled to ensure diversity of perspectives and demographic characteristics and appropriate balance of relationships with industry. Relevant author disclosures are included in Supplemental Table S1. Before appointment, members of the writing group were asked to disclose financial and intellectual relationships from the 12 months before their nomination. A majority of the writing group disclosed no relevant, significant financial relationships. The work of the writing committee was supported exclusively by SCAI, a nonprofit medical specialty society, without commercial support. Writing group members volunteered their contributions without compensation from SCAI. Readers should recognize that voluntary contributions may nevertheless confer commercial and reputational value to the authors.

Literature searches were performed by designated section leaders, and initial section drafts were drafted by small writing groups. Consensus statements were discussed and agreed upon by the full writing group using a modified Delphi process, which required 75% agreement among authors for a consensus. The draft manuscript was peer reviewed in June and July 2024, and the document was revised to address pertinent comments. The writing group unanimously approved the final version of the document. The SCAI Standards and Guidelines Committee and Executive Committee endorsed the document as official society guidance in October 2024.

SCAI statements are primarily intended to help clinicians make decisions about treatment alternatives. This consensus statement reflects the best available data at the time it was prepared along with the accumulated experience of the authors' expertise. The results of future studies may require revisions to the recommendations in this statement to reflect new data. This consensus statement is not intended to replace physicians' independent clinical judgment or medical advice, neither is the consensus statement intended to exclude other reasonable alternative procedures. The consensus statement is provided as a courtesy but not intended as a sole source of guidance in the evaluation of patients in need of aortic valve therapies. The ultimate judgment regarding any specific therapy must be made by the physician and the patient considering all circumstances presented by the individual patient and their illness and condition.

Imaging evaluation of access

Consensus Statements:

- A 2-scan strategy including an electrocardiogram (ECG)-gated scan of the aortic root and heart, immediately followed by a non–ECG-gated scan of the neck, thorax, abdomen, and pelvis during a contrast first-pass should be performed and analyzed in planning nonfemoral access TAVR

Computed tomography angiography acquisition and analysis

Volume (multislice) computed tomography angiography (CTA) with a large detector array is the preferred imaging modality for alternative access TAVR planning. It allows for a comprehensive evaluation of all access sites. Best practices for CTA acquisition include coverage that routinely extends from the base of the mandible (to incorporate carotid and proximal axillary arteries) to the proximal third of the thighs. To optimize image quality and contrast and radiation dose, a 2-step strategy is preferred: an ECG-gated volume scan of the aortic root and heart, followed immediately afterward by a non–ECG-gated scan of the vasculature including the neck, thorax, abdomen, and pelvis.[10] This can be achieved using 0.6 to 1.0 mL/kg of contrast administered once before the 2 combined acquisitions. For patients with kidney disease, minimal contrast should be used in an effort to reduce contrast-related kidney injury. Protocols requiring 0.2 of 0.5 mL/kg with slower flow rates and lower tube potential have been shown to be safe and to yield adequate image quality.[11–13] All computed tomography (CT) acquisition protocols should incorporate biphasic contrast administration, consisting of contrast injection followed immediately by saline flush. This can help avoid a streak artifact of undiluted contrast in the right heart, interference with aortic imaging, and minimization of potentially nephrotoxic excess undiluted contrast.[12] If iodinated contrast is contraindicated, a noncontrast CT for calcium assessment can be obtained in combination either with an arterial doppler ultrasound for sizing and disease assessment or with cardiovascular magnetic resonance imaging.[14,15]

Vascular access analyses should be performed using slices of ≤1.5 mm.[10] Most modern scans can provide slices of <0.5 mm. A comprehensive assessment of the valve delivery pathway is essential, including a detailed review of potential vascular access sites. Analysis should use curved multiplanar reformatting software tools to provide minimal lumen diameter, calcium burden (location, depth, and circumferential involvement), vessel tortuosity and arterial pathology (plaque, aneurysm, and dissection), and locations of nearby structures. The minimal lumen diameter for each currently FDA-approved valve is shown in Table 1. Operators are encouraged to carefully analyze image reconstructions on patients requiring alternative access.

Axillary/subclavian approach

Consensus statements:

- Percutaneous axillary access should be learned through proctorship and experience at least for the first 2 to 3 procedures; operators should be prepared to use additional bailout strategies to treat bleeding or vascular complications.
- Transaxillary access may be associated with a higher risk for neurologic complications, thus other extrathoracic access techniques should be favored compared with transaxillary access.

The axillary artery is an attractive route due to its extrathoracic location, relative ease for surgical or percutaneous access, and is of sufficient size for TAVR delivery systems. Transaxillary (infraclavicular) TAVR is often described incorrectly as trans-subclavian. Supraclavicular access via the true subclavian artery is uncommon, has been described via surgical exposure, and is difficult to distinguish from transaxillary access in large data sets.[16]

Patient screening/equipment/procedure

Although transaxillary access can be performed from a left-sided or right-sided approach, the left side may be preferred. The left axillary artery typically allows more favorable delivery angles relative to the aortic valve, appears less tortuous, and preserves the innominate artery for cerebral embolic protection, if necessary. Little evidence exists on this topic, although data from large-bore access registries for mechanical circulatory support suggest no significant difference in outcomes using either right or left access.[17,18] Relative contraindications to axillary artery access include an ipsilateral internal thoracic artery to coronary artery graft or axillary artery diameter 2.0 mm smaller than the expanded TAVR access sheath diameter. The presence of a pacemaker or defibrillator generator may also preclude transaxillary access on the ipsilateral side. Transaxillary access may cause greater radiation exposure to operators compared with transfemoral approaches.

Percutaneous and surgical axillary access technique

SCAI has published a position statement on best practices for percutaneous axillary arterial access, with detailed guidance on technique.[4] A detailed description of surgical transaxillary access has recently been published with step-by-step instructions.[19]

Postprocedural care and complications

Monitoring for hematoma and vascular complications is critical postprocedurally. The tissue planes associated with axillary access can accommodate a large amount of bleeding before it becomes clinically evident to staff. On discharge, patients should be instructed to avoid lifting >10 lb or raising the accessed limb above shoulder height for 1 week.

Close neurologic monitoring is important in light of the higher risk of stroke, to allow interventional neurorescue if appropriate. Some operators prefer local anesthesia to facilitate neurologic surveillance.[20] Brachial plexus injury remains a risk of either surgical or percutaneous approach.

Outcomes

Table 2[20–39] summarizes important observational outcome studies of transaxillary TAVR. The largest data set of transaxillary TAVR was

Table 1. Minimal vessel diameter for current FDA-approved transcatheter aortic valves

Company	Transcatheter heart valve	Valve size (mm)	Sheath size (F)	Minimal vessel diameter (mm)
Edwards Lifesciences	SAPIEN 3 Ultra	20, 23, 26	14	≥5.5
		29	16	≥6.0
Medtronic	Evolut FX/Evolut PRO+/Evolut R	23, 26, 29	14	≥5.0
	Evolut FX/Evolut PRO+	34	18	≥6.0
	Evolut R	34	16	≥5.5
Abbott	Navitor	23, 25	14	≥5.5
		27, 29	15	≥6.0

Table 2. Representative observational studies of nonfemoral access approaches for TAVR.

Reference, year	Enrollment period	Patients	STS 30-d PROM	30-d Death (%)	30-d Stroke+TIA (%)	LT or major bleeding (%)	Major vascular complication (%)	Length of stay (d)
Transaxillary access								
Schäfer et al,[21] 2017	2010-2016	100	7.2 ± 5.2	6.0	1.0	3.0	11[a]	7.9 ± 4.3
van der Wulp et al,[22] 2019	2008-2016	362	Not reported	5.2	1.7	11.9	5.2	6 (range, 4-8)
Gleason et al,[23] 2018	2010-2014	202	9.7 ± 5.9	5.4	7.4	39	11.9	8.3 ± 6.5
Dahle et al,[24] 2019	2010-2018	1180	7.7 ± 5.8	5.4	6.3	Not reported	2.5	3 (IQR, 2-5)
Debry et al,[25] 2020	2010-2018	113	5.8 (3.9-8.6)	5.5	3.5	3.6	8.0	9 (IQR, 6-11)
Amer et al,[26] 2020	2016-2018	38	12.0 ± 9.5	2.6	7.9	2.6	0.0	5.11 ± 4.77
Ooms et al,[20] 2021	2018-2020	35	4.3 ± 1.8	2.9	5.7	11	17.1	5 (IQR, 3-8)
Lederman et al,[27] 2022	2017-2020	106	5.7 (4.0-8.5)	6.6	13.0	13.2	0.9	6.2 ± 6.0
Kirker et al,[28] 2020	2015-2019	1576	7.0 ± 5.39	5.2	7.4	Not reported	2.2	3.0 (IQR, 2.0-5.0)
Allen et al,[29] 2023	2015-2021	1142	7.1 ± 5.1	4.3	5.9	10.6	2.5	3.0 (IQR, 2.0-4.0)
Giordano et al,[30] 2022	2019-2021	432	4.0	4.4	5.8	6.7	8.8	8.6
Weighted mean		**n = 5286**	**7.0**	**5.0**	**6.2**	**11.8**	**3.8**	**4.2**
Transcaval access								
Greenbaum et al,[31] 2017	2014-2016	100	9.6 ± 6.3	8	5	18	19[a]	4 (IQR, 2-6)
Costa et al,[32] 2020	2014-2019	50	8.6 ± 6.7	4	2	4[b]	14[a]	4 (IQR, 3-7)
Barbash et al,[33] 2021	2019-2021	20	4.1 (2.9-4.9)	10	10	10	5[a]	6 (IQR, 4-7)
Lederman et al,[27] 2022	2017-2020	238	5.0 (3.2-8.4)	5.9	2.9	10.1	2.5	4.8 ± 5.5
Michail et al,[34] 2022	2016-2021	8	0	0.0	0.0	0.0	0.0	2
Weighted mean		**n=416**	**6.40**	**6.2**	**3.6**	**11.1**	**7.1**	**4.5**
Transcarotid								
Debry et al,[25] 2020	2010-2018	201	5.5 (3.5-8.1)	4.5	7.0	5.5	8.5	8 (IQR, 6-11)
Junquera et al,[35] 2022	2015-2019	127	4.7 (3.2-6.8)	4.7	2.4	4.7	2.4	5.7 ± 3.4
Folliguet et al,[36] 2019	2013-2015	435	b	4.1	4.4	c	c	
Chamandi et al,[37] 2018	2012-2017	101	6.6 ± 5.7	5.0	3.0	4.0	3.0	8 (IQR, 6-11)
Overtchouk et al,[38] 2019	2014-2018	314	b	3.2	1.6	4.1	1.6	7 (IQR, 5-10)
Watanabe et al,[39] 2018	2012-2017	83	6.4 ± 3.3	8.4	1.2	c	1.2	12.4 ± 7.7
Amer et al,[26] 2020	2018-2020	33	15.1 ± 8.6	0.0	3.0	6	3.0	4 ± 2.7
Kirker et al,[28] 2020	2015-2019	788	7.6 ± 5.51	4.1	4.1	c	1.5	2.0 (IQR, 2.0-4.0)
Allen et al,[29] 2023	2015-2021	576	7.1 ± 5.2	3.6	3.1	8.2	2.1	2.0 (IQR, 2.0-4.0)
Weighted mean		**n = 2658**	**7.1%**	**4.1**	**3.6**	**6.3**	**2.4**	**4.2**

LT, life-threatening; PROM, predicted risk of mortality; STS, Society of Thoracic Surgeons; TIA, transient ischemic attack.
[a] Includes bailout stent-graft implantation. [b] Valve Academic Research Consortium 3 type 2+. [c] Nonstandard definition.

reported from the Society of Thoracic Surgeons (STS)/American College of Cardiology (ACC) Transcatheter Valve Therapy (TVT) Registry in 1249 patients who underwent transaxillary TAVR using the SAPIEN balloon-expandable system.[24] In the transaxillary group, Dahle et al[24] reported a high procedural success rate of 97.3%, with a low major vascular complication rate of 2.5%, but a stroke rate of 6.1%. Such reports often do not classify covered-stent implantation (a common part of transaxillary access) as a vascular complication, which confounds comparisons with other approaches. The CoreValve Extreme Risk US Pivotal trial reported a stroke rate of 7.5% in patients undergoing transaxillary approach[40] and a stroke rate of 6.5% in the CoreValve United States Pivotal Trial Program among patients undergoing transaxillary TAVR.[23] These findings are consistent with a class effect of higher-than-expected stroke rates with transaxillary access rather than a valve-specific effect.

The ACCESS study, the largest prospective multicenter trial specifically for transaxillary access for TAVR to date, provides important data on contemporary outcomes.[41] The procedural access success rate was high at >97%, vascular access complications requiring intervention was 6.7%, and an overall stroke rate of 8.0% (4.0% of which were debilitating). The ACCESS study did not demonstrate a significant difference in other procedural adverse events, length of stay, or 30-day outcomes related to right vs left laterality or in patients who underwent a completely percutaneous approach vs surgical cutdown. Compared with surgical access, percutaneous transaxillary access was associated with greater use of moderate sedation, shorter hospital stays, and lower ICU utilization. Pacemakers were more common after surgical access, and other outcomes were similar, including stroke.[42]

In summary, despite high rates of procedural success, periprocedural stroke rates are consistently elevated in the 6% to 8% range with the transaxillary approach and appear independent of valve selection, surgical vs percutaneous access, laterality, or center experience.

Transcaval approach

Consensus statements

- Preprocedural CT should be performed and analyzed to identify transcaval access targets, their position relative to fluoroscopic landmarks, and projection angles and to facilitate contingency planning for bailout covered stents.
- Transcaval access should be learned through teaching, proctorship, and review at least for the first 2 to 3 procedures.

The premise of transcaval access is that in a closed retroperitoneal space, interstitial pressure exceeds venous pressure. Aortic bleeding therefore can safely decompress directly into the venous system through a nearby IVC hole, rather than accumulate as retroperitoneal hemorrhage. Isolated IVC holes in the closed retroperitoneum do not generally cause important bleeding. In addition, iliofemoral veins are larger and more elastic than iliofemoral arteries to accommodate large sheaths. These observations demonstrate that transient aortocaval fistula as part of transcaval access can be safely tolerated for TAVR,[31] thoracic endovascular aortic repair,[43] and mechanical circulatory support such as Impella (Abiomed).[44]

Femoral vein transcaval access offers familiar transfemoral-like operator ergonomics and reduced radiation exposure compared with other nonfemoral artery access techniques, and similar risk of iatrogenic stroke compared with femoral artery access.[27]

Patient screening, equipment, and procedure

A step-by-step guide to the procedure and list of necessary equipment is published separately.[5] A patient-specific CT-guided plan identifies the access route and traversal angles, device sizes required for balloon-aortic tamponade, and suitable bailout covered stents.

Moderate sedation or general anesthesia are both feasible in transcaval access. For traversal, a stiff conductive guide wire is delivered within an insulating microcatheter, within a shorter microcatheter, within a still-shorter curved IVC guiding catheter. For ensnarement, a loop snare is draped across the right side of the aorta using a coronary guiding catheter. The devices are positioned using CT-derived orthogonal fluoroscopic projection angles, including a "bullseye" projection into the properly positioned aortic snare. The guide wire is advanced while briefly energized via radiofrequency current as it exits the IVC and crosses the aortic wall. Without further electrification, it is advanced through the snare. The ensnared guide wire is advanced to the high thoracic aorta. For TAVR sheath delivery, a very rigid guide wire is exchanged through the microcatheter. The TAVR sheath is then advanced from femoral vein to the aorta, and the TAVR device is delivered per standard of care procedures.

For aortocaval port closure, after protamine reversal of unfractionated heparin anticoagulation and positioning of a buddy/bailout guide wire, a deflectable guiding catheter rotates a nitinol occluder device sideways while its distal tip is partly exposed but constrained (bulbed). The aortic disc of the nitinol occluder is then released sideways in the aorta lumen and retracted toward the cava. With the disc abutting the aortic wall, the device neck is then exposed to anchor the device and finally released, if suitably positioned.

Challenges and postprocedural care

With the transcaval TAVR sheath in place, the procedure is indistinguishable from transfemoral. After TAVR, anticoagulation is fully reversed before deployment of the nitinol occluder device to minimize bleeding.

Completion aortography, preferably using digital subtraction and breath-hold, reveals 3 patterns: complete occlusion, residual aortocaval fistula, or hemorrhage. Only the third is actionable and should be treated with immediate balloon-aortic tamponade using an oversized compliant balloon at low pressure. If aortic closure is still unsatisfactory, covered-stent implantation is required in approximately 1% to 2% of cases.[31,32] Rarely, patients with severe pulmonary artery hypertension or right ventricular dysfunction do not tolerate residual left-to-right shunting and require covered-stent implantation. Venous angiography or intervention has never appeared warranted. Convalescence after transcaval access follows standard transfemoral care pathways; next day discharge is common, although the length of stay may be slightly higher on average.[27]

Complications and outcomes

In an early prospective study that included systematic follow-up CT (N = 100) and independent source-data verification, transcaval TAVR procedural success was 98%, major or life-threatening bleeding was 12%, transfusion was 35%, and major vascular complications (including covered-stent implantation) were 13%. At 12 months, there were no additional vascular complications, and only 1% of aortocaval fistulae were proven patent.[45] These complications were lower in a retrospective European series (N = 50).[32] In a contemporary retrospective series (N = 238), the rate of major or life-threatening bleeding was 10%, transfusion was 19%, and major vascular complications was 3%.[27]

Transcaval and transfemoral access are essentially identical above the diaphragm. The incidence of stroke and acute kidney injury appear comparable between transfemoral (2%) and transcaval (3%) approaches,[27] although early transcaval experience showed a slightly higher stroke rate (5%)[31]; however, ineligibility for transfemoral access confers a higher risk of all complications.[46] In addition, the likelihood of discharge directly home without stroke appears similar, in contrast to transaxillary access.[27] Outcomes may improve with adoption of best practices,[5] smaller TAVR delivery systems, and the development of purpose-built access and closure systems. New operators may achieve proficiency during fellowship or after 1 to 3 proctored procedures.[5] Closure techniques can be simulated using an inexpensive benchtop model/jig assembled from hardware store components.[5]

Transcarotid approach

Consensus statements

- Specialized cranial/cerebral imaging other than standard TAVR protocol CTA studies should not be routinely performed for transcarotid access planning.
- Transcarotid TAVR should be learned through teaching, proctorship, and experience at least for the first 2 to 3 procedures.

The carotid artery is a convenient site for access owing to its extrathoracic location, size, proximity to skin, ease of surgical exposure, and often favorable angle to the ascending aorta. Early concerns for an increased risk for stroke are not supported by contemporary outcomes data. A step-by-step guide to the procedure has been published previously.[47]

Preoperative imaging/evaluation

Standard TAVR CTA, which includes the lower carotid artery, is sufficient to determine suitability for transcarotid access. Carotid duplex ultrasonography, while no longer routine, may be useful in assessment of transcarotid access.[48–50] Additional cerebral imaging to document an intact circle of Willis or CTA of the neck is unnecessary. Selection of the right or left carotid artery is guided by transfemoral sizing criteria, vessel tortuosity, and the presence of internal carotid artery stenosis. For some operators, valve selection can be driven by planned carotid access route. The carotid artery with the worst internal carotid artery stenosis on carotid duplex should be used because this carotid will be occluded during the procedure. A previous carotid endarterectomy is not a contraindication but increases the risk of cranial nerve injury.

Carotid artery exposure/intraoperative monitoring

Transcarotid access is performed with general anesthesia in >90% of patients and is usually preferred for patient comfort.[28,29,50] Exposure of the carotid artery requires minimal instruments and no special catheters or techniques. The carotid artery is exposed low in the neck at the level of the omohyoid through an incision parallel and anterior to the sternocleidomastoid muscle. No adjunct cerebral monitoring is recommended specific for transcarotid TAVR; however, maintaining systolic blood pressure of >140 mm Hg is desirable.[48,51,52] Transcarotid access

may cause greater radiation exposure to operators compared with transfemoral approaches.

The carotid artery is accessed with a needle, and a soft tip guide wire is passed into the ascending aorta. A small sheath is then inserted, the aortic valve is crossed, and a coiled stiff wire is placed into the left ventricle. The carotid artery distal to the stiff wire is clamped, and the more proximal artery is snared with an umbilical tape with removal of the small sheath. A transverse arteriotomy is made, incorporating the stiff guide wire that will allow atraumatic insertion of the large sheath into the carotid artery. A self-expanding transcatheter heart valve (THV) can be inserted using the inline sheath; alternatively, an 18F sheath can be used to ease catheter exchanges for hemodynamic measurements and valvuloplasty if needed. The balloon-expandable THV can be delivered using either the Certitude (Edwards Lifesciences) or Commander (Edwards Lifesciences) delivery system depending on operator preference.

Following valve deployment, the delivery system/sheath is removed, the carotid arteriotomy is primarily repaired, and flow is reestablished to the brain. The incision is closed without a drain after the reversal of unfractionated heparin. Patients are extubated at the end of the procedure and monitored briefly in a recovery unit before transferring to the floor for routine care.

Outcomes

Transcarotid access has become the most commonly used nonfemoral access technique in North America (Figure 1). Large observational series of transcarotid access (Table 2) demonstrate acceptable complication rates. The weighted mean stroke/transient ischemic attack (TIA) rate at 30 days was 3.6%, while vascular complications were reported at 2.4%, and major bleeding occurred at a weighted mean of 6.3%. These rates are compared with transaxillary and transcaval alternative access techniques below.

There are several potential explanations for the similar or lower stroke rate with transcarotid access compared with other nonfemoral access sites. During the procedure, clamping the distal common carotid artery and flushing potential debris before unclamping may protect the ipsilateral cerebral hemisphere from emboli. In addition, transcarotid access typically avoids traversing the origin of the vertebral arteries and

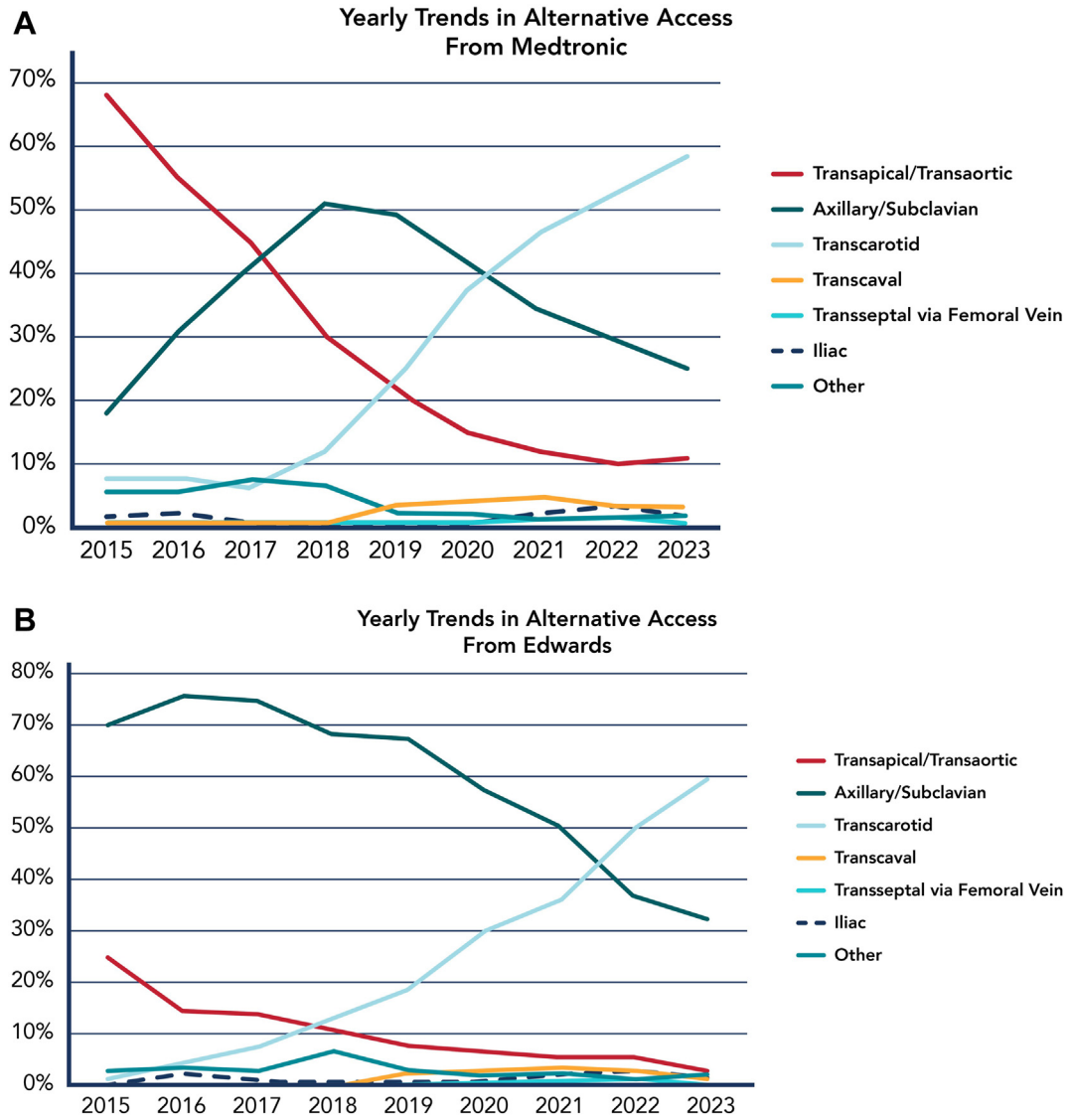

Figure 1.
Yearly trends in alternate access use for TAVR: (**A**) SAPIEN (3, Ultra, and Resilia) valves and (**B**) Evolut (R, PRO, PRO+, and FX) valves. TAVR, transcatheter aortic valve replacement.

offers a direct route into the ascending aorta, thereby minimizing guide wire and device interaction with the aortic arch.

In summary, transcarotid access is simple, does not violate the thoracic cavity, reduces guide wire and catheter interaction with the aortic arch, uses few disposable equipment, and is relatively easy to teach while providing acceptably low stroke rates and short length of stay.

Intrathoracic access: transapical and transaortic

Consensus statements:

- Extrathoracic (transcarotid, transcaval, and transaxillary/subclavian) access should be preferred over intrathoracic (transaortic and transapical) nonfemoral access for TAVR to reduce morbidity and mortality.

Transapical and transaortic access

Currently, transapical and/or transaortic access are primarily considered when transaxillary, transcaval, or transcarotid TAVR are not feasible. Transapical TAVR was the first alternative access site for TAVR and served as the primary alternative access for the PARTNER I clinical trial, enabling antegrade placement of the valve through a lateral apical incision. Transaortic access followed soon after, providing an invasive technique for retrograde placement of the valve. There was limited research into purpose-built technology for direct transaortic access; however, it did not gain wide use due to its invasive nature.[53]

Transapical TAVR—operative technique

The surgical approach to transapical TAVR has been illustrated and described in detail in a previous publication.[54] Preoperative chest CT imaging guides proper location of the left anterior thoracotomy in the fifth or sixth intercostal space; direct inspection and echocardiography permit identification of the left ventricular apex where sutures will be placed. The apex is accessed with a needle, and a soft J guide wire is passed across the aortic valve with transesophageal echocardiographic guidance into the ascending aorta. The guide wire is exchanged for a stiff guide wire, and a large sheath is established in the left ventricular apex. After valve deployment and assessment, the large sheath is removed under conditions of rapid pacing, and the insertion site is secured with purse-string sutures, taking care to avoid tearing of the myocardium. Reinforcement stitches are placed as needed. The chest is closed in standard fashion.

Transaortic TAVR—operative technique

Transaortic access TAVR has been described in step-by-step detail in previous publications[55,56] and is summarized here briefly. It is accomplished via an upper partial sternotomy or an anterior R thoracotomy. Sutures are placed in the distal ascending aorta to control the large sheath site. The center of the suture site is accessed, a sheath is placed, and the aortic valve is crossed with a catheter and straight guide wire. A stiff "working" guide wire is then established, and a large sheath is positioned with ~2.0 cm depth in the aorta and held securely. The TAVR valve and delivery system are then delivered to the annulus, and the valve is deployed. After valve assessment, the large sheath is removed, and the insertion site is secured with purse-string sutures.

Outcomes

A higher risk of adverse events with transapical (vs transfemoral) TAVR was initially recognized from a substudy analysis within the PARTNER I trial. Using propensity score matching, Blackstone et al[57] compared transapical and transfemoral cases and found that patients treated with transapical approach had higher early mortality, longer length of stay, and longer overall recovery despite similar stroke rates compared with those treated with transfemoral. In addition, a single-center, observational study compared outcomes of patients who underwent transapical vs transfemoral TAVR from 2011 to 2020.[58] Despite higher early procedural risk associated with transapical TAVR, 5-year survival was similar to those seen in transfemoral TAVR.[58]

A recent meta-analysis compared extrathoracic vs intrathoracic TAVR approaches in 18 studies published through 2023.[59] More than 5000 patients treated with extrathoracic TAVR were compared with 6800 patients who underwent intrathoracic TAVR. Intrathoracic access was associated with an increased risk of all-cause mortality at 30 days and 1 year (relative risk [RR], 1.99 and 1.31, respectively) vs extrathoracic TAVR. Intrathoracic access was associated with a higher risk for major postoperative complications at 30 days compared with extrathoracic TAVR. This included a higher risk for acute kidney injury requiring renal replacement (RR, 2.11; 95% CI, 1.53-2.92), life-threatening bleeding (RR, 1.71; 95% CI, 1.41-2.07), and new-onset atrial fibrillation/flutter (RR, 2.69; 95% CI, 1.47-4.93). Those undergoing intrathoracic access were also significantly more likely to be discharged to a facility other than home (RR, 2.60; 95% CI, 1.12-6.04). There was no difference in stroke rates between these approaches. In summary, extrathoracic approaches appear preferable over intrathoracic approaches when femoral access is unsuitable for TAVR.[3,59]

Augmented transfemoral access (IVL, percutaneous balloon angioplasty, bare metal, and covered stenting)

Multiple reports and case series have demonstrated the feasibility of iliofemoral intervention before transfemoral TAVR in patients with severe calcific iliofemoral disease, the so-called crack-and-pave approach where percutaneous balloon angioplasty and adjunct stenting is performed in advance of transfemoral TAVR. This can be done either in a staged fashion or as a concomitant approach. Alternatively, IVL of the common and/or external iliac artery can facilitate transfemoral TAVR access in selected individuals.[60] The types of calcific lesions or patterns of calcium distribution most amenable to IVL has not been clearly defined. The relative risk of interventional endovascular approach pre-TAVR vs standard transfemoral TAVR is not known. A recent single-center observational study compared clinical outcomes in patients treated with traditional transfemoral TAVR vs transfemoral TAVR with peripheral vascular intervention (PVI) vs nontransfemoral TAVR. While the authors concluded that transfemoral TAVR and transfemoral TAVR with PVI had similar clinical outcomes, nearly 90% of PVI was performed as bailout for complications, and only 11% of PVI was performed before TAVR to facilitate transfemoral access.[61] Data published from a nationwide claims database showed that clinical outcomes are generally worse in patients who undergo PVI plus TAVR vs those who undergo TAVR only,[62] but they lack the granularity to understand whether PVI was used to prepare for TAVR. These data did suggest that whether PVI is used as bailout or to facilitate transfemoral TAVR, clinical outcomes such as short-term mortality, hospital length of stay, and 30-day readmission may be better compared with nonfemoral, alternative access TAVR. Further research is necessary to explore the efficacy, safety, and appropriate strategy for combining PVI with TAVR in patients with peripheral artery disease. As TAVR delivery systems improve and both experience and technology advances with augmented transfemoral access (including the use of intravascular), this

may become a more frequently chosen technique for patients with prohibitive femoral vessels. Operators with greater peripheral intervention experience may find this preferable to nonfemoral approaches.

Comparison of nonfemoral TAVR access approaches

Consensus Statements

- When anatomically feasible, transcarotid or transcaval access are generally preferable to transaxillary access.
- The decision of alternative access route for TAVR should be individualized to each patient based on CT evaluation of anatomical factors, patient risk factors and preferences, and multidisciplinary heart team discussions.

Table 2 shows representative studies of transcaval, transaxillary/subclavian, and transcarotid access. No randomized comparisons of nonfemoral access techniques are available. All published reports are observational. The best available data are abstracted from the STS/ACC TVT registry, and data collected from approximately 2016-2017 onward particularly appear most applicable as they represent latest techniques and latest generation of low-profile TAVR devices. Our recommendations derive from a survey of the published literature, clinical experience, and clinical judgment of a range of physician experts. All complications appear to be higher in nonfemoral vs femoral access cases, and this most likely reflects higher comorbidity and complexity among patients ineligible for femoral access.[46]

Transcarotid vs transaxillary/subclavian

Table 2 suggests that mortality and major/life-threatening bleeding and major vascular complications appear to be similar after transcarotid vs transaxillary access. Stroke appears consistently less common after transcarotid than that after transaxillary access. The rate of discharge directly to home appears to be significantly higher after transcarotid access than that after transaxillary access (83%-88% vs 70%-75%).

These inferences are best supported by a pair of propensity-matched studies (N = 4082) from the STS/ACC TVT registry comparing transcarotid with transaxillary approaches for the most common balloon-expandable[28] and self-expanding[29] TAVR devices. Transcarotid access using a CoreValve[29] (Medtronic) was associated with a lower stroke rate at 30 days (3.1% vs 5.9%; $P = .017$) and 1 year (3.4% vs 7.2%; $P = .003$), with transaxillary access being a multivariable predictor for stroke (hazard ratio, 2.14; 95% CI, 1.27-3.58; $P = .004$) or stroke or death (hazard ratio, 1.63; 95% CI, 1.11-2.42; $P = .014$) at 30 days. Procedural benefits of transcarotid access included a shorter procedure time (99 vs 118 min; $P < .001$), less fluoroscopy time (18.0 vs 18.8 min; $P = .02$), shorter hospital length of stay (median 2 vs 3 days; $P < .001$), and more frequent discharge to home (88.4% vs 80.7%; $P < .001$).

An increased stroke signal was also observed at 30 days (7.4% vs 4.2%; $P = .003$) with transaxillary vs transcarotid access in a propensity-matched STS/ACC TVT Registry analysis using the SAPIEN 3 (Edwards Lifesciences) THV.[28] Similar to CoreValve, transcarotid access using SAPIEN 3 was also associated with a shorter procedure time (117.0 vs 132.4 min; $P < .001$), reduced fluoroscopy time (16.6 vs 21.6 min; $P < .001$), lower contrast volume (78.5 vs 96.7 mL; $P < .001$), shorter hospital stay (2.0 vs 3.0 days; $P = .002$), and more frequent discharge to home (82.9% vs 74.6%; $P < .001$). Although there are no randomized comparisons, the benefits of transcarotid over transaxillary access appears agnostic of THV type and supports the increasing use of transcarotid access over transaxillary approaches.[28,29]

Transcaval vs transaxillary/subclavian

Table 2 suggests that the risk of mortality and major/life-threatening bleeding are similar between transcaval and transaxillary access. Stroke appears consistently less common after transcaval than that after transaxillary access. Possible differences in major vascular complications are unclear because studies variably classify covered-stent implantation as routine rather than as a complication. The rate of discharge directly to home appears to be significantly higher after transcaval access that that after transaxillary access (93% vs 70%).

These inferences are supported by the single contemporary comparison of transcaval and transaxillary access (n = 344), which used inverse-propensity weighting to correct for confounders.[27] Nearly 350 patients at 8 centers who underwent TAVR through transaxillary or transcaval access were compared, with >7100 patients undergoing transfemoral TAVR. Patients who underwent transaxillary TAVR had significantly higher rates of stroke/TIA compared with those undergoing transcaval TAVR or transfemoral TAVR (13.2% vs 2.9% vs 2.1%, respectively; $P < .001$). Rates of major or life-threatening bleeding were similar between transcaval and transaxillary cases (10.1% vs 13.2%), both higher than those undergoing transfemoral TAVR (3.5%).

Synthesizing available observational data, transcarotid and transcaval access both appear to be superior to transaxillary and other nonfemoral access approaches. Both appear to have a lower rate of stroke and a higher rate of discharge directly to home than those of transaxillary access. Figure 2 compares the unique features of all 3 approaches.

Transcarotid and transcaval approaches have not been compared directly. While transcarotid requires low-risk surgical access, the transcaval technique is fully percutaneous. In considering the logistics, transcarotid access is better performed under general anesthesia, while transcaval TAVR is readily performed using moderate sedation and has ergonomics indistinguishable from standard femoral access. Potential cost differences between transcarotid (additional cost of operative and anesthesia staff) and transcaval (additional cost of equipment) appear difficult to ascertain. In situations where individual patient anatomy does not clearly favor transcarotid or transcaval and both are feasible, the choice of access can be left to the discretion of the local heart team based on preference and experience.

Role of proctoring

Consensus statements

- Institution-specific structural heart teams should focus on gaining proficiency in 1 or 2 alternative access techniques.
- Physician proctoring can be part of a comprehensive approach to adding new skillsets for less experienced operators and should involve a formal understanding of the role of the operator and proctor in training in new techniques.

Alternative access approaches often involve developing new skillsets. Techniques and best practices can be taught in fellowship; for those already in practice, learning can be facilitated by published "how to" articles, by didactic material developed by societies and/or industry partners, by courses developed to teach new access skills, and by case observation. Physician proctors play an important role and provide valuable guidance to teams preparing to deploy a new procedure or capability. SCAI has recently published a position paper on the role of physician proctors,[63] which is summarized here.

	Transaxillary or Trans-subclavian	Transcarotid	Transcaval
Mortality	Similar among extra-thoracic	Similar among extra-thoracic	Similar among extra-thoracic
Stroke	Higher than transfemoral	Similar or possibly more common than transfemoral	Similar or possibly more common than transfemoral
Bleeding	Higher than transcarotid	Standard for comparison	Higher than transcarotid
Vascular complications	Covered stents variable	Standard for comparison	Covered stents uncommon
Anesthesia	General anesthesia common	General anesthesia common	Moderate sedation common
Postoperative discomfort	Similar or elevated	Similar orelevated	Modest
Length of stay	Similar or elevated	Similar to transfemoral	Similar to transfemoral
Discharge directly to home	~80%	>90%	>90%
Ergonomics of TAVR ("operator comfort")	Less comfortable than transfemoral	Less comfortable than transfemoral	Same as transfemoral
Proximity to x-ray source and scatter (operator Radiation)	Closer to x-ray source and scatter than transfemoral	Closer to x-ray source and scatter than transfemoral	Same as transfemoral
Fully percutaneous option	Yes	No	Yes
Additional contrast and risk of acute kidney injury	More than transfemoral	Less than transfemoral	More than transfemoral
Cost of disposable and implanted devices	More than transcarotid	No implant	More than transcarotid
Cost of operating room or procedure space	Similar across approaches	Similar across approaches	Similar across approaches
Eligibility for embolic protection device	Sentinel eligible for left-sided only	Index carotid may be protected; Sentinel ineligible	Eligible
Training requirements	Comparable; requires specific training	Comparable; requires specific training	Comparable; requires specific training
Quality of supportive evidence	Observational; no randomized comparisons	Observational; no randomized comparisons	Systematic evaluation including CT; no randomized comparisons

Figure 2.
Qualitative comparison of extrathoracic nonfemoral access routes for TAVR. Color indicates relative appeal: green, favorable; orange, neutral; red, unfavorable. TAVR, transcatheter aortic valve replacement.

Role of physician proctoring

Physician proctorship helps to improve patient access to techniques that improve medical care, including alternative access for TAVR. Physician proctors do not have a doctor-patient relationship absent overt or implicit mutual consent.[64] Physician proctors must be proficient in both technique and complication management. Proctorship should be viewed as part of a "last mile" solution for new operators, including didactic training, observing experts using the technique, and reviewing the technique and patient-specific plans with experts immediately beforehand, before "live" onsite proctoring. "Reverse proctoring," where teams travel to observe experienced operators perform alternative access procedures, are especially useful for both physicians and staff. The onsite physician proctor's role is one of an advisor; the ultimate responsibility for all aspects of the procedure lies with the operative team. The patient should be made aware that a proctor will be present and that the role of the proctor will be as an advisor and not physician-operator. The proctor will be present in the procedure and can be scrubbed so as not to risk sterility protocols but should not take any physical role in the procedure. The proctor should participate in the

case preparation in advance of the procedure and during the debrief and help to assess the site's readiness to proceed free of proctor. While industry has traditionally played a significant role in providing proctor training and support, it is recommended that institutions strongly consider independent support of proctors and that societies engage in training and certification of proctors when feasible.

Conclusions and future directions

There have been important advances in delivery systems and techniques leading to more streamlined transfemoral TAVR approaches; however, as the overall number of patients undergoing TAVR in an all-indications world has increased, alternative access remains a significant challenge. Additionally, while new observational data with current devices have provided insights into the safety of alternative access practices, there are no prospective randomized trials in this area. We acknowledge the lack of the highest quality of evidence in this space and have done our best to synthesize the available evidence.

In light of the limited available data, when femoral artery access is not suitable, it is our recommendation that extrathoracic access be selected over intrathoracic access and that transcarotid and transcaval approaches be preferred over transaxillary/subclavian access. All 3 extrathoracic nonfemoral access routes appear to confer similar mortality, but transcarotid and transcaval approaches appear to confer significantly lower risk of stroke across multiple published series as well as significantly higher rates of direct discharge to home rather than to nursing facilities. Head-to-head comparisons of transcarotid with transcaval approaches are not available, and the literature does not clearly support 1 route over another; we make no statement regarding the preference between these routes and recommend either of these 2 routes (transcarotid or transcaval) when alternative access is needed. Institutional and operator experience should be considered when selecting an alternative access route in cases if patient anatomy does not clearly dictate a preferred technique between transcarotid and transcaval. Refinements in technique and development of novel tools for alternative access will continue to develop and inform this decision.

While IVL and percutaneous angioplasty and stenting are frequently used, limited data support aggressive attempts at transfemoral access in the setting of small or excessively diseased iliofemoral arteries. There is a need for rigorous studies to evaluate concomitant peripheral intervention techniques (including IVL) used to facilitate transfemoral access and to examine the safety and comparative effectiveness of PVI plus TAVR with alternative nonfemoral access approaches to TAVR. For these difficult cases, careful patient selection and a team-based approach involving endovascular specialists is necessary for optimal patient care.

When a site encounters a case requiring an alternative access technique for which they lack requisite experience or a plan to acquire it, we recommend transfer to a more experienced site to offer the best possible care to the patient.

We believe SCAI and related societies should support standardized training and proctorship of all vascular access approaches; whenever possible, this should be independent of industry support. Given the relative infrequency of alternative arterial access approaches, there is likely a volume-outcome relationship with these access techniques. Additionally, the variety of techniques available likely leads to significant variation in clinical practice. As such, there is a clear clinical need to standardize alternative access routes and best practices to improve the technique and safety of these high-risk procedures. Repetition of best practices will grow experience and competence among operators.

Finally, prospective comparisons of contemporary transcarotid and transcaval access for TAVR to determine both short-term and long-term efficacy and safety would be of value; however, given that frequently only 1 of these access routes might be available in any given patient, continued refinement and ongoing development of adjunct techniques and equipment to improve ease of use and outcomes for both transcarotid and transcaval access should be pursued.

Declaration of competing interest

Matthew Sherwood is in the consulting/advisory board for Medtronic and a site investigator for Abbott (internal project on TEER and GDMT). Paul D. Mahoney reports serving as a consultant and proctor for Edwards Lifesciences, Medtronic, and Boston Scientific and on the advisory council of Abbott and Boston Scientific. Santiago Garcia reports serving as a proctor and on a steering committee for Edwards Lifesciences. Keith Allen is a speaker and proctor for Edwards Lifesciences, Medtronic; a proctor for Abbott; and a PI for Abbott (SUMMIT Trial). Thom Dahle reports serving as a proctor for Edwards Lifesciences, Medtronic, and Boston Scientific. Chandan Devireddy reports serving as a consultant for Medtronic and Edwards Lifesciences. Kendra J. Grubb reports serving as a speaker, consultant, and advisory panel member for Medtronic. Tsuyoshi Kaneko reports serving as a consultant and advisory board member for Edwards Lifesciences. Robert J. Lederman is a coinventor on patent applications assigned to his employer, the National Institutes of Health, on devices to facilitate transcaval access procedures. Puja B. Parikh, Marie-France Poulin, and Anene Ukaigwe report associations with Medtronic. Carlos Sanchez reports serving as a proctor for Medtronic, Edwards Lifesciences, Boston Scientific, and Abbott. All other authors reported no financial interests.

Funding sources

Dr Lederman's participation was supported by NIH Z01-HL006040 (to R.J.L.). All other aspects of this document were supported entirely by SCAI.

Supplementary material

To access the supplementary material accompanying this article, visit the online version of the *Journal of the Society for Cardiovascular Angiography & Interventions* at 10.1016/j.jscai.2024.102514.

References

1. Kaneko T, Vemulapalli S, Kohsaka S, et al. Practice patterns and outcomes of transcatheter aortic valve replacement in the United States and Japan: a report from joint data harmonization initiative of STS/ACC TVT and J-TVT. *J Am Heart Assoc*. 2022;11(6):e023848. https://doi.org/10.1161/JAHA.121.023848
2. Carroll JD, Mack MJ, Vemulapalli S, et al. STS-ACC TVT registry of transcatheter aortic valve replacement. *J Am Coll Cardiol*. 2020;76(21):2492–2516. https://doi.org/10.1016/j.jacc.2020.09.595
3. Kaneko T, Hirji SA, Yazdchi F, et al. Association between peripheral versus central access for alternative access transcatheter aortic valve replacement and mortality and stroke: a report from the Society of Thoracic Surgeons/American College of Cardiology Transcatheter Valve Therapy Registry. *Circ Cardiovasc Interv*. 2022;15(9):e011756. https://doi.org/10.1161/CIRCINTERVENTIONS.121.011756
4. Seto AH, Estep JD, Tayal R, et al. SCAI position statement on best practices for percutaneous axillary arterial access and training. *J Soc Cardiovasc Angiogr Interv*. 2022;1(3):100041. https://doi.org/10.1016/j.jscai.2022.100041
5. Lederman RJ, Greenbaum AB, Khan JM, Bruce CG, Babaliaros VC, Rogers T. Transcaval access and closure best practices. *J Am Coll Cardiol Intv*. 2023;16(4):371–395. https://doi.org/10.1016/j.jcin.2022.12.005
6. Arai T, Romano M, Lefèvre T, et al. Direct comparison of feasibility and safety of transfemoral versus transaortic versus transapical transcatheter aortic valve replacement. *J Am Coll Cadiol Intv*. 2016;9(22):2320–2325. https://doi.org/10.1016/j.jcin.2016.08.009
7. Otto CM, Nishimura RA, Bonow RO, et al. 2020 ACC/AHA guideline for the management of patients with valvular heart disease. *J Am Coll Cardiol*. 2021;77(4):e25–e197. https://doi.org/10.1016/j.jacc.2020.11.018
8. Vahanian A, Beyersdorf F, Praz F, et al. 2021 ESC/EACTS guidelines for the management of valvular heart disease. *Eur Heart J*. 2022;43(7):561–632. https://doi.org/10.1093/eurheartj/ehab395

9. Szerlip M, Al-Azizi K, Alasnag M, et al. SCAI publications committee manual of standard operating procedures: 2022 update. *J Soc Cardiovasc Angiogr Interv*. 2022;1(4):100389. https://doi.org/10.1016/j.jscai.2022.100389
10. Blanke P, Weir-McCall JR, Achenbach S, et al. Computed tomography imaging in the context of transcatheter aortic valve implantation (TAVI)/transcatheter aortic valve replacement (TAVR). *J Am Coll Cardiol Img*. 2019;12(1):1–24. https://doi.org/10.1016/j.jcmg.2018.12.003
11. Lacy SC, Benjamin MM, Osman M, Syed MA, Kinno M. Low contrast and low kV CTA before transcatheter aortic valve replacement: a systematic review. *J Cardiovasc Imaging*. 2023;31(2):108. https://doi.org/10.4250/jcvi.2022.0108
12. Pulerwitz TC, Khalique OK, Nazif TN, et al. Very low intravenous contrast volume protocol for computed tomography angiography providing comprehensive cardiac and vascular assessment prior to transcatheter aortic valve replacement in patients with chronic kidney disease. *J Cardiovasc Comput Tomogr*. 2016;10(4):316–321. https://doi.org/10.1016/j.jcct.2016.03.005
13. Spagnolo P, Giglio M, Di Marco D, et al. Feasibility of ultra-low contrast 64-slice computed tomography angiography before transcatheter aortic valve implantation: a real-world experience. *Eur Heart J Cardiovasc Imaging*. 2016;17(1):24–33. https://doi.org/10.1093/ehjci/jev175
14. Francone M, Budde RPJ, Bremerich J, et al. CT and MR imaging prior to transcatheter aortic valve implantation: standardisation of scanning protocols, measurements and reporting—a consensus document by the European Society of Cardiovascular Radiology (ESCR). *Eur Radiol*. 2020;30(5):2627–2650. https://doi.org/10.1007/s00330-019-06357-8
15. Reindl M, Lechner I, Holzknecht M, et al. Cardiac magnetic resonance imaging versus computed tomography to guide transcatheter aortic valve replacement: a randomized, open-label, noninferiority trial. *Circulation*. 2023;148(16):1220–1230. https://doi.org/10.1161/CIRCULATIONAHA.123.066498
16. Dahle TG, Castro NJ, Stegman BM, et al. Supraclavicular subclavian access for sapien transcatheter aortic valve replacement—a novel approach. *J Cardiothorac Surg*. 2018;13(1):16. https://doi.org/10.1186/s13019-018-0706-9
17. McCabe JM, Kaki AA, Pinto DS, et al. Percutaneous axillary access for placement of microaxial ventricular support devices: the axillary access registry to monitor safety (ARMS). *Circ Cardiovasc Interv*. 2021;14(1):e009657. https://doi.org/10.1161/CIRCINTERVENTIONS.120.009657
18. Khan S, Gregory V, Isath A, et al. CARC8: right versus left axillary artery access in Impella 5.5 insertion. *ASAIO J*. 2023;69(Supplement 2):43. https://doi.org/10.1097/01.mat.0000943468.71830.f8
19. Harloff MT, Percy ED, Hirji SA, et al. A step-by-step guide to trans-axillary transcatheter aortic valve replacement. *Ann Cardiothorac Surg*. 2020;9(6):510–521. https://doi.org/10.21037/acs-2020-av-79
20. Ooms JF, Van Wiechen MP, Hokken TW, et al. Simplified trans-axillary aortic valve replacement under local anesthesia—a single-center early experience. *Cardiovasc Revasc Med*. 2021;23:7–13. https://doi.org/10.1016/j.carrev.2020.11.025
21. Schäfer U, Deuschl F, Schofer N, et al. Safety and efficacy of the percutaneous transaxillary access for transcatheter aortic valve implantation using various transcatheter heart valves in 100 consecutive patients. *Int J Cardiol*. 2017;232:247–254. https://doi.org/10.1016/j.ijcard.2017.01.010
22. van der Wulp K, Verkroost MWA, van Wely MH, et al. Feasibility and outcomes of transcatheter aortic valve implantation using the left axillary artery as primary access site. *Ann Thorac Surg*. 2019;107(2):546–552. https://doi.org/10.1016/j.athoracsur.2018.07.093
23. Gleason TG, Schindler JT, Hagberg RC, et al. Subclavian/axillary access for self-expanding transcatheter aortic valve replacement renders equivalent outcomes as transfemoral. *Ann Thorac Surg*. 2018;105(2):477–483. https://doi.org/10.1016/j.athoracsur.2017.07.017
24. Dahle TG, Kaneko T, McCabe JM. Outcomes following subclavian and axillary artery access for transcatheter aortic valve replacement: Society of the Thoracic Surgeons/American College of Cardiology TVT Registry Report. *J Am Coll Cardiol Intv*. 2019;12(7):662–669. https://doi.org/10.1016/j.jcin.2019.01.219
25. Debry N, Trimech TR, Gandet T, et al. Transaxillary compared with transcarotid access for TAVR: a propensity-matched comparison from a French multicentre registry. *EuroIntervention*. 2020;16(10):842–849. https://doi.org/10.4244/EIJ-D-20-00117
26. Amer MR, Mosleh W, Joshi S, et al. Comparative outcomes of transcarotid and transsubclavian transcatheter aortic valve replacement. *Ann Thorac Surg*. 2020;109(1):49–56. https://doi.org/10.1016/j.athoracsur.2019.05.035
27. Lederman RJ, Babaliaros VC, Lisko JC, et al. Transcaval versus transaxillary TAVR in contemporary practice: a propensity-weighted analysis. *J Am Coll Cardiol Intv*. 2022;15(9):965–975. https://doi.org/10.1016/j.jcin.2022.03.014
28. Kirker E, Korngold E, Hodson RW, et al. Transcarotid versus subclavian/axillary access for transcatheter aortic valve replacement with SAPIEN 3. *Ann Thorac Surg*. 2020;110(6):1892–1897. https://doi.org/10.1016/j.athoracsur.2020.05.141
29. Allen KB, Watson D, Vora AN, et al. Transcarotid versus transaxillary access for transcatheter aortic valve replacement with a self-expanding valve: a propensity-matched analysis. *JTCVS Tech*. 2023;21:45–55. https://doi.org/10.1016/j.xjtc.2023.07.019
30. Giordano A, Schaefer A, Bhadra OD, et al. Percutaneous vs. surgical axillary access for transcatheter aortic valve implantation: the TAXI registry. *Panminerva Med*. 2022;64(4):427–437. https://doi.org/10.23736/S0031-0808.22.04750-4
31. Greenbaum AB, Babaliaros VC, Chen MY, et al. Transcaval access and closure for transcatheter aortic valve replacement: a prospective investigation. *J Am Coll Cardiol*. 2017;69(5):511–521. https://doi.org/10.1016/j.jacc.2016.10.024
32. Costa G, De Backer O, Pilgrim T, et al. Feasibility and safety of transcaval transcatheter aortic valve implantation: a multicentre European registry. *EuroIntervention*. 2020;15(15):e1319–e1324. https://doi.org/10.4244/EIJ-D-19-00797
33. Barbash IM, Segev A, Berkovitch A, et al. Clinical outcome and safety of transcaval access for transcatheter aortic valve replacement as compared to other alternative approaches. *Front Cardiovasc Med*. 2021;8:731639. https://doi.org/10.3389/fcvm.2021.731639
34. Michail M, Cockburn J, Tanseco KVP, et al. Feasibility of transcaval access TAVI in morbidly obese patients: a single-center experience. *Catheter Cardiovasc Interv*. 2022;100(7):1302–1306. https://doi.org/10.1002/ccd.30465
35. Junquera L, Kalavrouziotis D, Côté M, et al. Results of transcarotid compared with transfemoral transcatheter aortic valve replacement. *J Thorac Cardiovasc Surg*. 2022;163(1):69–77. https://doi.org/10.1016/j.jtcvs.2020.03.091
36. Folliguet TA, Teiger E, Beurtheret S, et al. Carotid versus femoral access for transcatheter aortic valve implantation: a propensity score inverse probability weighting study. *Eur J Cardiothorac*. 2019;56(6):1140–1146. https://doi.org/10.1093/ejcts/ezz216
37. Chamandi C, Abi-Akar R, Rodés-Cabau J, et al. Transcarotid compared with other alternative access routes for transcatheter aortic valve replacement. *Circ Cardiovasc Interv*. 2018;11(11):e006388. https://doi.org/10.1161/CIRCINTERVENTIONS.118.006388
38. Overtchouk P, Folliguet T, Pinaud F, et al. Transcarotid approach for transcatheter aortic valve replacement with the sapien 3 prosthesis: a multicenter French registry. *J Am Coll Cardiol Intv*. 2019;12(5):413–419. https://doi.org/10.1016/j.jcin.2018.11.014
39. Watanabe M, Takahashi S, Yamaoka H, et al. Comparison of transcarotid vs. transfemoral transcatheter aortic valve implantation. *Circ J*. 2018;82(10):2518–2522. https://doi.org/10.1253/circj.CJ-18-0530
40. Petronio AS, De Carlo M, Bedogni F, et al. Safety and efficacy of the subclavian approach for transcatheter aortic valve implantation with the corevalve revalving system. *Circ Cardiovasc Interv*. 2010;3(4):359–366. https://doi.org/10.1161/CIRCINTERVENTIONS.109.930453
41. Dahle TG, Stegman BM, Dutcher JR, et al. Subclavian-axillary access for transcatheter aortic valve implantation with SAPIEN 3: results from the ACCESS study. *Struct Heart*. 2020;4(6):487–493. https://doi.org/10.1080/24748706.2020.1822566
42. Chung CJ, Kaneko T, Tayal R, Dahle TG, McCabe JM. Percutaneous versus surgical transaxillary access for transcatheter aortic valve replacement: a propensity-matched analysis of the US experience. *EuroIntervention*. 2022;17(18):1514–1522. https://doi.org/10.4244/EIJ-D-21-00549
43. Uflacker A, Lim S, Ragosta M, et al. Transcaval aortic access for percutaneous thoracic aortic aneurysm repair: initial human experience. *J Vasc Interv Radiol*. 2015;26(10):1437–1441. https://doi.org/10.1016/j.jvir.2015.07.024
44. Afana M, Altawil M, Basir M, et al. Transcaval access for the emergency delivery of 5.0 liters per minute mechanical circulatory support in cardiogenic shock. *Catheter Cardiovasc Interv*. 2021;97(3):555–564. https://doi.org/10.1002/ccd.29235
45. Lederman RJ, Babaliaros VC, Rogers T, et al. The fate of transcaval access tracts: 12-month results of the Prospective NHLBI Transcaval Transcatheter Aortic Valve Replacement Study. *J Am Coll Cardiol Intv*. 2019;12(5):448–456. https://doi.org/10.1016/j.jcin.2018.11.035
46. Palmerini T, Saia F, Kim WK, et al. Vascular access in patients with peripheral arterial disease undergoing TAVR. *J Am Coll Cardiol Intv*. 2023;16(4):396–411. https://doi.org/10.1016/j.jcin.2022.12.009
47. McKiernan M, Grubb KJ, Guyton RA, Paone G. Transcarotid transcatheter aortic valve replacement. *Oper Tech Thorac Cardiovasc Surg*. 2021;26(2):224–243. https://doi.org/10.1053/j.optechstcvs.2020.12.001
48. Allen KB, Chhatriwalla AK, Cohen D, et al. Transcarotid versus transapical and transaortic access for transcatheter aortic valve replacement. *Ann Thorac Surg*. 2019;108(3):715–722. https://doi.org/10.1016/j.athoracsur.2019.02.007
49. Kirker EB, Hodson RW, Spinelli KJ, Korngold EC. The carotid artery as a preferred alternative access route for transcatheter aortic valve replacement. *Ann Thorac Surg*. 2017;104(2):621–629. https://doi.org/10.1016/j.athoracsur.2016.12.030
50. Allen KB, Chhatriwalla AK, Saxon J, et al. Transcarotid versus transthoracic access for transcatheter aortic valve replacement: a propensity-matched analysis. *J Thorac Cardiovasc Surg*. 2022;164(2):506–515. https://doi.org/10.1016/j.jtcvs.2020.09.133
51. Allen KB. Commentary: transcarotid TAVR—keeping it simple. *Oper Tech Thorac Cardiovasc Surg*. 2021;26(2):244–245. https://doi.org/10.1053/j.optechstcvs.2021.06.011
52. Allen KB, Chhatriwalla AK. The 10 commandments of transcarotid transcatheter aortic valve replacement. *Innovations (Phila)*. 2023;18(3):217–222. https://doi.org/10.1177/15569845231174022
53. Kiser AC, O'Neill WW, De Marchena E, et al. Suprasternal direct aortic approach transcatheter aortic valve replacement avoids sternotomy and thoracotomy: first-in-man experience. *Eur J Cardiothorac Surg*. 2015;48(5):778–784. https://doi.org/10.1093/ejcts/ezu524
54. Cheung A, Lichtenstein KM. Illustrated techniques for transapical aortic valve implantation. *Ann Cardiothorac Surg*. 2012;1(2):231–239. https://doi.org/10.3978/j.issn.2225-319X.2012.07.12
55. Caskey M, Pan H, Kirshner M, et al. Transcatheter aortic valve replacement using the transaortic approach. *Ann Cardiothorac Surg*. 2017;6(5):561–564. https://doi.org/10.21037/acs.2017.09.05

56. Lardizabal JA, O'Neill BP, Desai HV, et al. The transaortic approach for transcatheter aortic valve replacement: initial clinical experience in the United States. *J Am Coll Cardiol*. 2013;61(23):2341–2345. https://doi.org/10.1016/j.jacc.2013.02.076
57. Blackstone EH, Suri RM, Rajeswaran J, et al. Propensity-matched comparisons of clinical outcomes after transapical or transfemoral transcatheter aortic valve replacement: a placement of aortic transcatheter valves (PARTNER)-I trial substudy. *Circulation*. 2015;131(22):1989–2000. https://doi.org/10.1161/CIRCULATIONAHA.114.012525
58. Mork C, Twerenbold R, Gahl B, et al. Similar 5-year survival in transfemoral and transapical TAVI patients: a single-center experience. *Bioengineering (Basel)*. 2023;10(2):156. https://doi.org/10.3390/bioengineering10020156
59. Abellan C, Antiochos P, Fournier S, et al. Extrathoracic against intrathoracic vascular accesses for transcatheter aortic valve replacement: a systematic review with meta-analysis. *Am J Cardiol*. 2023;203:473–483. https://doi.org/10.1016/j.amjcard.2023.07.091
60. Kempton H, Roy A, Watson A, Evans D, Muller D, Roy D. Using intravascular lithotripsy to facilitate transfemoral arterial access for transcatheter aortic valve implantation. *Heart Lung Circ*. 2022;31(11):e135–e139. https://doi.org/10.1016/j.hlc.2022.07.016
61. Isogai T, Agrawal A, Shekhar S, et al. Comparison of outcomes following transcatheter aortic valve replacement requiring peripheral vascular intervention or alternative access. *J Am Heart Assoc*. 2023;12(12):e028878. https://doi.org/10.1161/JAHA.122.028878
62. Bansal A, Kalra A, Kumar A, et al. Outcomes of combined transcatheter aortic valve replacement and peripheral vascular intervention in the United States. *J Am Coll Cardiol Intv*. 2021;14(23):2572–2580. https://doi.org/10.1016/j.jcin.2021.08.024
63. Seto AH, Duffy PL, Don CW, et al. SCAI position statement on best practices for clinical proctoring of new technologies and techniques. *J Soc Cardiovasc Angiogr Interv*. 2022;1(3):100036. https://doi.org/10.1016/j.jscai.2022.100036
64. Patient-physician relationships. AMA-Code. Accessed March 25, 2024. https://code-medical-ethics.ama-assn.org/chapters/patient-physician-relationships