Biliary system

08 January 2022 15:21

BILIARY SYSTEM

Congenital Choledochal Cyst

* Cystic dilation of Bile duct d/t Congenital weakness in Biliary system

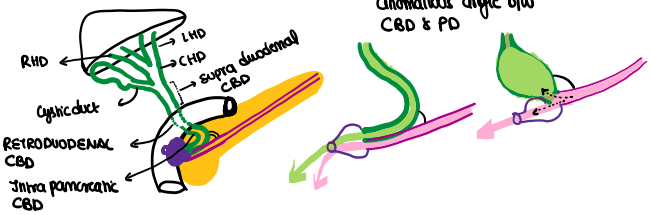

TODANI'S Classn

TYPE : I : FUSIFORM



TYPE : II : DIVERTICULUM

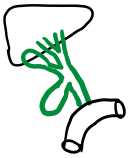

TYPE : III : Intra pancreatic CHOLEDOCHOCELE

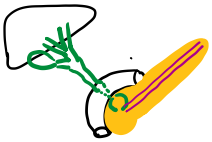

TYPE IVA

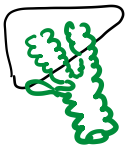

TYPE IVB

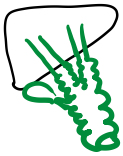

TYPE : V : Caroli's dz.

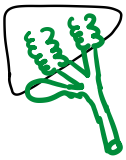

multiple cyst	✓	✓	✓
Intra	✓	✗	✓
Extra	✓	✓	✗

m/c Type : I > IV > III

↑ R/F malignancy : ↑ cholangio·Ca, ↑ GB·Ca] max· chance for malignant transformation : IVa

C/F : Age : 10- 20yrs

TRIAD

- ✓ palpable Right upper abdominal mass
- ✓ obstructive Jaundice
- ✓ Abdominal pain

→ 1st INV : USG

IOC : MRCP

Mx :
- I → Roux-en-y Hepatojejunostomy
- II → " " " "
- III → Endoscopic cyst deroofing
- IVa → liver Tx
- IVb → Roux-en-y
- V → liver Tx

Complications

- ✱ CBD stones
- ✱ Cholangitis
- ✱ Cholangio· Ca
- ✱ GB· Ca

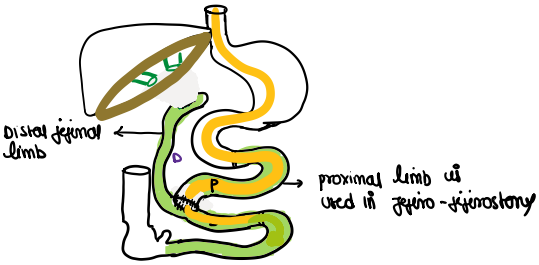

CHOLELITHIASIS

Gall Stones :- 90% Radiolucent
- 10% Radio opaque

Cholestrol Stones ← Dirty white

© 1. Lithogenic Bile :
- Obesity
- Bile acid ↓
- Ileal Resection
- CYP7A
- lecithin ↓
- MDR-3 mutatio

2. Hypomotile Gall Bladder
- ✱ Prolonged fasting
- ✱ TPN : long duration
- ✱ Pregnancy.
- ✱ massive BURNS
- ✱ Octreotide.

3. Nucleating factors
- ✱ Infections
- ✱ DM

Pigmented Stones

BLACK	BROWN
© : Hemolytic disorder - H. spherocytosis - SCA - β-Thalassemia - prosthetic Heart valve	© E. coli & Klebsiella ↓ β - Glucoronidase ↓ Conjugated Bile → Unconjugated Bile ↓ Brown Pigment Stones
Composition Ca. Phosphate Ca. Bicarbonate	Composition Ca. Palmatate Ca. Stearate
Radio - opaque	Radio opaque

mixed (m/c)

Complications a/w Gall stones

Gall Bladder
- m/c → ① Acute Cholecystitis
- 2. Chronic " "
- 3. mucocele of GB
- 4. Empyocele "
- 5. GB necrosis
- 6. GB perforation
- 7. GB Carcinoma

CBD
- 1. Obstructive Jaundice
- 2. Cholangitis
- 3. CBD Stricture

Pancreas
- 1. Acute pancreatitis

Bowel
- 1. Gall Stone ileus
- 2. BOUVERET Synd.

ACUTE CHOLECYSTITIS

↓ Inflammation of Gall Bladder

CALCULOUS Cholecystitis
↓
- Inflammation 2° to Gall Stones

ACALCULOUS Cholecystitis
↓
- Severe Hypovolemia
- Emphysematous Cholecystitis → m/c organism © : Clostridium
- Xanthogranulomatous " " → m/c aerobic © : E. coli

└→ Ruptured Rokitansky Ascoff sinus.

C/F : TRIAD
- Pain
  - ↓ Radiating (RHC)
    - Epigastric ↓ (Vagus)
    - ® Tip of Shoulder ↓ (Phrenic N)
    - ® Infra angle of Scapula ↓ (T7)
- Fever
- Leukocytosis

O/E : murphy's sign ⊕ : mid Inspiratory arrest on deep palpation in RHC.

IOC : USG → Edema in Gall Bladder
Gall Bladder wall >3mm thickness Q.

BEST : H.I.D.A : Hepato Biliary Imino Diacetic Acid Scan
- Non visualization of GB c̄ in 30 mins of inj. H.I.D.A

Mx

<72 hrs
↓
lap. cholecystectomy

>72 hrs
↓
Conservative mx
- IVF
- IV analgesia
- IV antibiotics
- N.P.O

↓ > 4-6 wks

Internal Cholecystectomy

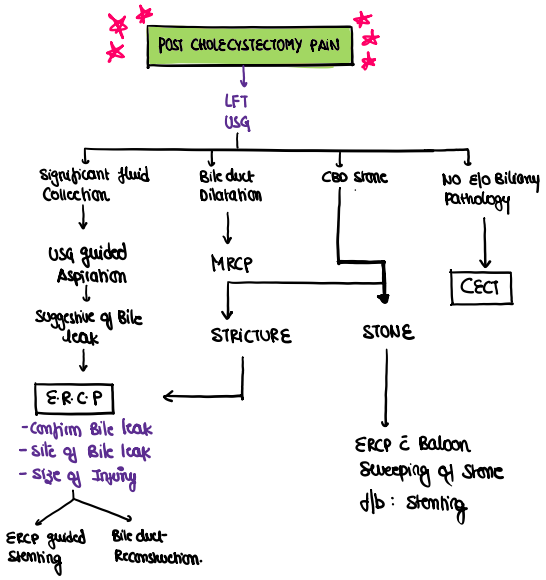

POST CHOLECYSTECTOMY PAIN

LFT
USG

- Significant fluid Collection → USG guided Aspiration → Suggestive of Bile leak → E.R.C.P
- Bile duct Dilatation → MRCP → STRICTURE → E.R.C.P ; MRCP → STONE
- CBD stone → STONE → ERCP c̄ Baloon Sweeping of Stone d/b : Stenting
- NO E/O Biliary Pathology → CECT

E.R.C.P
- Confirm Bile leak
- Site of Bile leak
- Size of Injury

→ ERCP guided Stenting
→ Bile duct Reconstruction.

BILE DUCT INJURIES

✓- lap Sx > open Sx
✓- poor visual perception

STRASBERG Clasn : Bile duct Injury

CLASS A :



- Bile leak from GB fossa or Cystic duct stump leak

CLASS B :

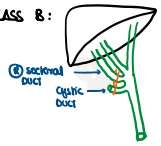

- Injury to Ⓡ sectoral duct Resulting in obstruction of Bile flow

CLASS C :

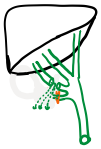

- Injury to Ⓡ sectoral duct Resulting in Bile leak from Ⓡ sectoral duct.

CLASS D:



- lateral injury to Extra hepatic Bile duct c̄ Bile leak.

CLASS E : Post-op Biliary Stricture

↓

BISMUTH Clasn

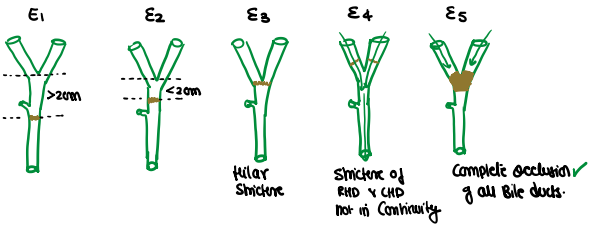

E3: Hilar Stricture
E4: Stricture of RHD & CHD not in Continuity
E5: Complete occlusion of all Bile ducts. ✓

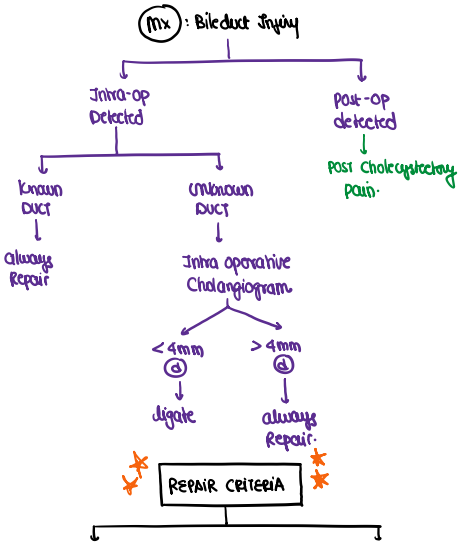

Ⓜx : Bileduct Injury

- Intra-op Detected
  - Known Duct → always Repair
  - Unknown Duct → Intra operative Cholangiogram
    - < 4mm ⓓ → ligate
    - > 4mm ⓓ → always Repair.
- Post-op detected → post Cholecystectomy pain.

REPAIR CRITERIA

< ½ Circumference
< 180°

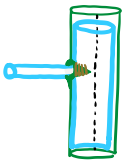

- Primary Repair Over T-TUBE

> ½ Circumference
> 180°

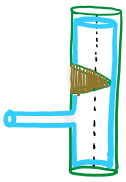

- Primary Repair of Bile duct
- T-TUBE from a diff site

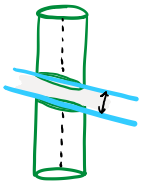

< 1cm : Primary Repair & T-TUBE from Diff. site
> 1cm : Roux-en-y Heparojejunostomy

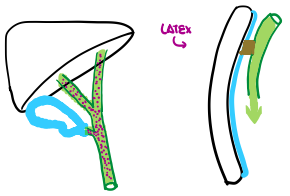

T-TUBE is removed after 10-14 days

	MUCOCELE of GB	EMPYOCELE OF GB	MIRIZZES synd
	* Gall Bladder distended due to Retention of mucus 2° to a large impacted Stone @ Neck of GB	* Infected mucocele of GB.	* External Compression of the CHD d/t gall stone or Gall stone induced Complication
	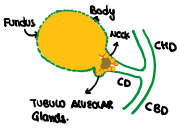 Fundus Body Neck CHD CD CBD TUBULO ALVEOLAR Glands.		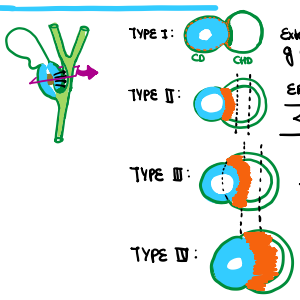 TYPE I : External Compression of CHD. TYPE II : EROSION of CHD <1/3rd of circumference TYPE III : EROSION of CHD 1/3 - 2/3rd of circumference TYPE IV : EROSION of CHD >2/3rd – whole Circumference TYPE V : Bilio-Enteric Fistula.
C/F	* RHC discomfort * RHC mass → Globular, Rounded, Smooth GB mass → - Globular - move c̄ Respiration - Costal margin free **COUVISIER'S LAW** : Distended palpable GB, it is seldom 2° to stone. Ⓔ: mucocle of GB	s/s of mucocele + - RHC pain - High grade fever	s/s of Cholecystitis + Obstructive Jaundice
Ist INV :	USG	USG	USG
JOC :	USG	USG	MRCP
Mx :	Early lap. chole	Early lap. chole	Type : I – Partial Cholecystectomy II, III – Partial cholecystectomy + Choledochoplasty (STENT) IV, V – Roux-en-y Heparojejunostomy

Gall Stone ileus

* Small Bowel dynamic obstruction 2° to gall stones

Ⓒ : BILIO-Enteric FISTULA

1. Chole cysto duodenal Fistula : m/c/s
2. Chole cysto Colic Fistula

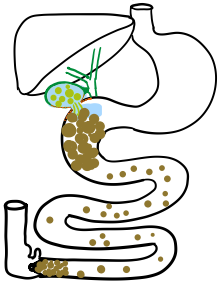

C/F : AGE : 60-70yrs
SEX : F > M

* s/s of Small Bowel #
- Colicky abdominal pain
- Nausea & vomiting
- Non passage of Stools & flatus

INV : X-Ray → - multiple air fluid levels
- pneumobilia
- impacted stone @ T-ileum +/-

RIGLER'S TRIAD Q.
↓
No need for Cholecystectomy

Mx : **Exploratory laprotomy**

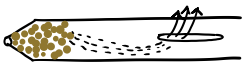

- Enterotomy is performed proximal To Obstruction
- milk the stones & remove
- Close Enterotomy

Ectopic Gall Stones

Q.

BOUVERET Synd : Gastric outlet obstruction 2° to Gall stones

Gall Bladder Cancer

m/c type : Adeno Ca

m/c site : Fundus

R/F
- * congenital Choledochal cyst
- * FAP , HNPCC
- * Typhoid Carrier
- * Chronic Cholecystitis
- * Gall stones
- * porcelian GB
- * Hyper Estrogenemia
- * Smoking
- * Adenomatous polyp > 1cm.

Morphology

- Diffuse Infiltrating Type
  - m/c
  - a/w : worst prog.
- Nodular
- papillary
  - a/w : Best prog.

C/F : AGE : 50- 55yrs
SEX : F > M

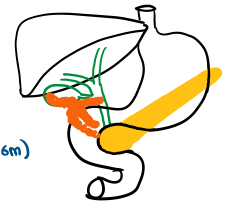

- * Acute Cholecystitis
- * vauge Epigastric dyscomfort
- * Significant wt. loss (>10% ~6m)
- * mucocele of GB : @ Neck

Advanced.
- * Obstructive Jaundice
- * Abdominal pain : colicky

Ist : USG

IOC : Tripple phase -CT

m/c route of spread : DIRECT : [GB lacks sub mucosa]

m/c/s for 2° : liver.

TNM-Class^{n}

T1a : ⊕ lamina Propria

T1b : ⊕ muscular layer

T2a : ⊕ perimuscular C.T - peritoneal side

T2b : ⊕ " " - Hepatic side

T3 : DIRECT Invasion :
- LIVER
- Extra hepatic Bile duct
- stomach
- Duodenum
- pancreas
- omentum or
- Colon.

T4 : ⊕ Portal vein (main)
⊕ Hepatic. a
≥ 2 Extra hepatic organ

N1 : 1-3 Regional Nodes ⊕

N2 : ≥ 4 " " "

M0 : ✗

M1 : ✓

Mx

T1A | Simple Cholecystectomy

T1B, T2 | Radical Cholecystectomy → GB + 4b, 5 + lymph nodes along Hepato duodenal ligament

Cystic Duct Stump : FROZEN → ⊕ Tumour cells : Roux-en-y

T3, T4 | NEO-ADJUVANT CHEMO : Gemcitabine
- Good → Radical Cholecystectomy
- Poor → palliative mx

CHOLEDOCHOLITHIASIS

CBD - Stones

- 1°
  - Stone is formed in CBD
  - m/c type : Brown
- 2° (m/c)
  - Stone is formed in GB and lodged into CBD
- Retained
  - CBD stone c̄ in 2yrs of cholecystectomy

C/F
- * Asymptomatic
- * Obstructive jaundice
- * Cholangitis

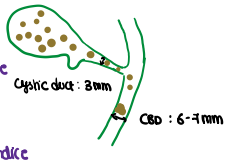

CHARCOTS TRIAD : pain, Fever, Jaundice

⊕ Septic shock, Altered Sensorium

→ RAYNOLDS PENTARD

JOC : MRCP

Mx

- ✓ I : NPO, IVF, IV- analgesia, IV- antibiotics — 24/48hs.
- ✓ II : > 24/48hs : ERCP + Stone Extraction + CBD Stenting
- ✓ III : > 7-10days : lap. cholecystectomy.

CHOLANGIOCARCINOMA

R/F
- * Primary sclerosing Cholangitis
- * Oriental Cholangiohepatitis
- * HCV
- * Opisthorchis Viverrii
- * Clonorchis Sinensis
- * C.C. Cyst
- * Vinyl chloride
- * Thorium dioxide
- * Biliary Enteric Anastamosis.

C/F : Age > 60yrs

SEX : F > M

m/c s : Hilum

BISMUTH - CORLETTE Clasn

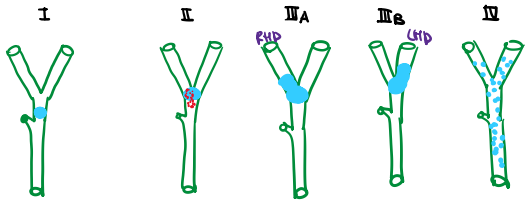

- I : Below Hilum
- II : @ Hilum — Klatskin Tumour — m/c Type
- IIIA : Hilar Ca. Extending into RHD
- IIIB : Hilar Ca. Extending in LHD
- IV : multicentric

C/F
- * painless, persistent progressive jaundice
- * Anorexia
- * Fatigue
- * Significant weight loss
- * malena

1st INV : USG

JOC : MRCP + MRI

TM : ↑ CEA, ↑ CA 19-9

Mx

- Hilar ca
  - Caudate lobectomy
  - CBD Resection
  - Lymphadenectomy → PORTO Enteric (KASAI's) Anastamosis Sx
- Distal Cholangio ca
  - Whipples Sx
- unresectable Tumour
  - palliative mx
    - Obstructive Jaundice : ERCP + Stenting
    - Chemo : Gemcitabine + Cisplatin.