Stomach

11 January 2022 17:44

STOMACH

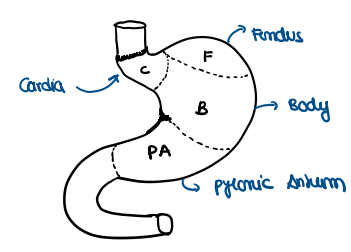
Fundus
F
Cardia
C
B
Body
PA
Pyloric Antrum

Cell Type	Q. Location	Function
1. Parietal cells	Body	HCl + Castel Intrinsic factor → B12 absorption
2. Mucus	Body & Antrum	mucus + HCO_3^-
3. Cheif cells	Body	Pepsin
4. E.C.L cells	Body	Histamine
5. G-cells	Antrum	Gastrin
6. D-cells	Body & Antrum	Somatostatin

Acid physiology

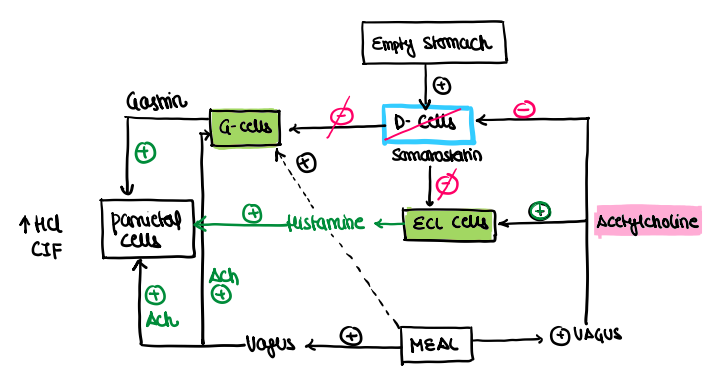
Empty Stomach
⊕
D-Cells
Somatostatin
∅
G-cells
⊕
Gastrin
⊕
Parietal cells
↑ HCl
CIF
⊕ Histamine
ECL cells
⊕
⊖
Acetylcholine
Ach ⊕
⊕ Ach
Vagus
⊕
MEAL
⊕ VAGUS

VAGUS

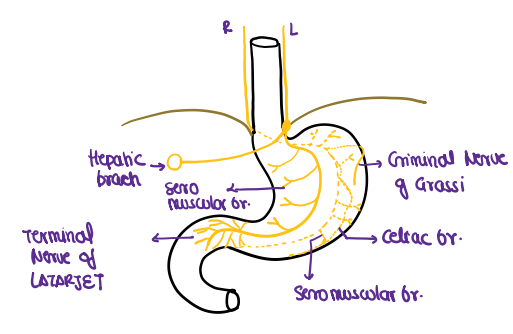
R
L
Hepatic branch
Sero muscular br.
Terminal Nerve of LATARJET
Criminal Nerve of Grassi
Celiac br.
Seromuscular br.

Blood Supply

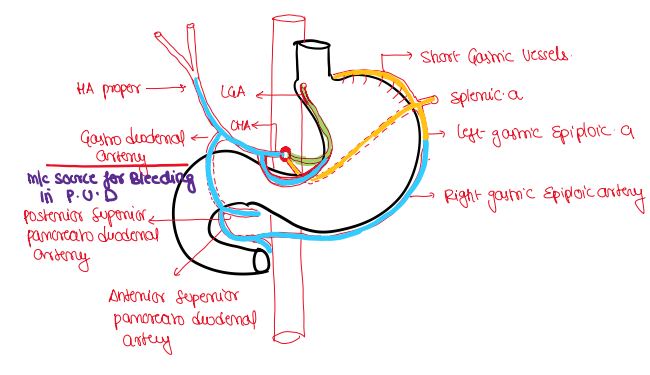
HA proper
LGA
CHA
Gastro duodenal artery
m/c source for Bleeding in P.U.D
Posterior Superior pancreato duodenal artery
Anterior superior pancreato duodenal artery
Short Gastric Vessels
Splenic a
left gastric Epiploic a
Right gastric Epiploic artery

CHPS : Congenital hypertrophic pyloric stenosis

Since Birth → ↑ Size of Circular muscles → pyloric region → Narrowing → Gastric outlet obstruction.

C/F : Age : 3rd – 6th wk (4th wk)

Sex : M > F (4 : 1)

1st BORN MALE CHILD : ↑ R/F

Pathogenesis

Ⓡ Episodes of vomiting

- Non Bilious vomiting
- Projectile vomiting
- Extensive cry just before vomiting

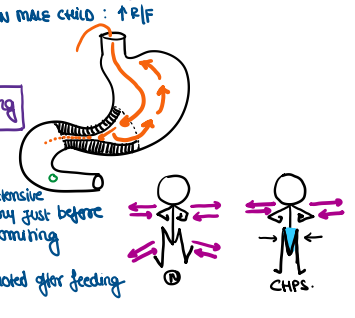

O/E
- ✓ olive lump : Best noted after feeding
- ✓ Visible peristalysis
- ✓ Starvation stools : only mucus
- ✓ Dehydrated

S. Electrolyte : $H_2O + HCl + Na^+$

H^+ O^- → - m. Alkalosis

Cl^- → - Hypochloremia, - Hypokalemia, - paradoxical Aciduria

Na^+ → ⊕ Aldosterone

A : Absorption of Na^+ & H_2O

B : BP. maintains

C, D : CD of nephron → Na^+ K^+ / Na^+ H^+

E : Excreation of K^+

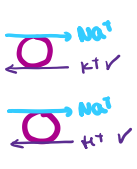

1st INV : X-Ray : massive fundus gas.

JOC : USG : Double Track app

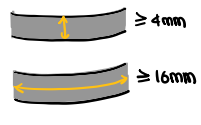

→ CHPS.

Q. Mx : SxOC : Lap. Ramsteds pyloro myotomy

DUODENAL ATRESIA

Incomplete or Improper chanalization b/w Fore gut & mid gut

FORE GUT	MID GUT	HIND GUT
D2	D3 to T⅔ colon.	Dentate line.

C/F : Age : Day 1 / Day 2

Sex : M = F

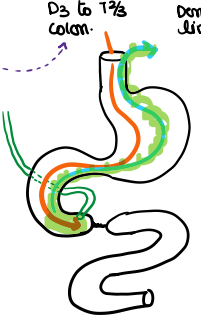

- ✓ Ⓡ Episodes of vomiting ≥ 30mins of feeding
- ✓ Bilious vomiting
- ✓ Non Projectile

INV : X-Ray → Double Bubbel Sign : Duodenal Atresia

→ Tripple Bubbel Sign : Jejunal Atresia

A/w Other Congenital Anomalies
- ✓ Annular pancreas
- ✓ Down Syndrome
- ✓ Extra hepatic Biliary Atresia

Mx : Exploratory laprotomy → Duodenoduodenostomy

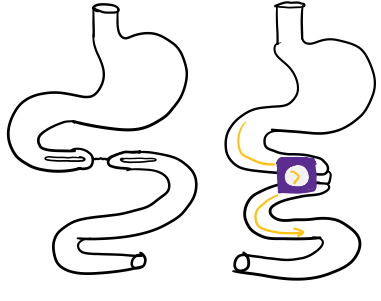

Peptic Ulcer Disease : P.U.D

a/w Gastric type of mucosa

Breech in Continuity of mucus membrane.

- Duodenum (D1) (m/c)
- Stomach
- Lower ⅓ Esophagus
- Meckel's Diverticulum.

Stomach → modified Johnson's Classⁿ

Type I :

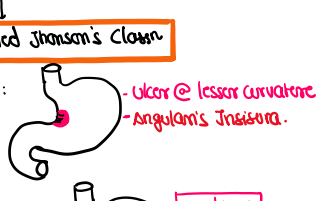
- Ulcer @ lesser curvature
- Angularis Insisura.

Type II :

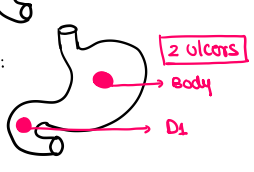
2 ulcers
Body
D1

Type III :

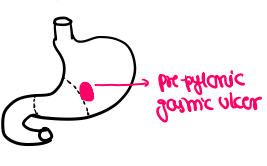
pre-pyloric gastric ulcer

Type IV :

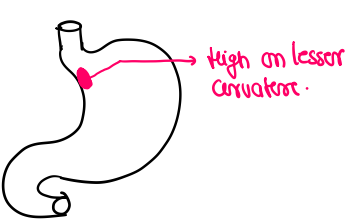
High on lesser curvature.

Type V : N.S.A.I.D.S induced Gastric ulcer.

Ⓒ : Peptic Ulcer Disease

- ✱ H. pylori → 85-90% Duodenal Ulcer, → 75% Gastric ulcer
- ✱ Smoking
- ✱ NSAIDS
- ✱ Steroids
- ✱ Stress ulcers → BURNS : CURLING ULCER; Head injury : CUSHING ULCER
- ✱ Endocrine Ⓒ : - Gastrinoma (Zollinger Ellison synd) - Cushing Syndrome - Hyper para thyroidism.

Pathophysiology

	Duodenal ulcer	Gastric ulcer : PRE-malignant
m/c/s :	D1	Angularis Insisura
Status :	Hyper acidic	Normo acidic / Hypoacidic
Pain :	≥ 2 hrs of Eating	Immediatly after eating Food pain Severe
Intensity :	mild to mod.	
Appetite :	↑↑	↓↓
Weight :	Gain	loss
Bleeding :	-	m/c → posterior Gastric ulcer ↓ m/c source : Gastroduodenal artery
Perforation :	m/c → Anterior ulcers perforate.	-

JOC : U.G.I.E

Gastric ulcer

Biopsy from all quadrants.
- No Cancer → H. Pylori Eradication
- Adeno ca

Tripple therapy : PPI + Broad spectrum AB + Imidazole; Quadraple therapy : Tripple + Bismuth / Sucralfate — 10-14 days

→ Repeat Endoscopy → ulcer
- Healed → observation & followup c̄ annual UGIE
- Persistent → Ⓡ Biopsy
  - No Cancer → Surgical Excision → BILROTH-I, BILROTH-II, Antrectomy
  - Adeno Ca

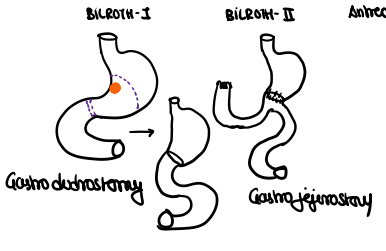
Gastroduodenostomy
Gastrojejunostomy

Duodenal ulcer → H. Pylori Eradication → fails → Surgery
- Truncal vagotomy
- Selective vagotomy
- Highly selective vagotomy

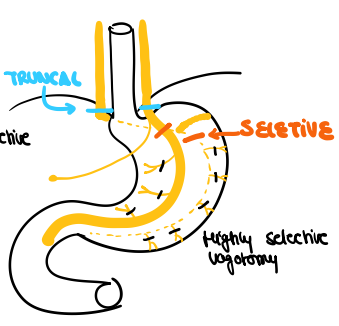
TRUNCAL
SELETIVE
Highly selective vagotomy

SURGERY : ↓ maximum acid out put

TRUNCAL VAGOTOMY + Antrectomy.

Complications of P.U.D

✱ Bleeding (Hemorrhage) → Gastric ulcers, posteriorly situated ulcer, m/c source : Gastro duodenal a

Upper G.I Bleeding

JOC : UGIE : FORREST CLASSIFICATION

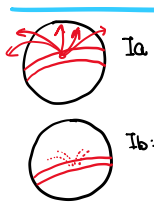

Ia : Active pulsatile Bleeding Visible Blood vessel

Ib : Oozing of Blood Visible Blood Vessel.

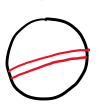

IIa : Non Bleeding Visible Blood Vessel.

High Risk for Recurrance.

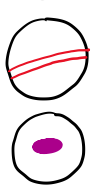

IIb : Adherant clot — Intermediate R/F Recurrance.



IIc : Black Dot

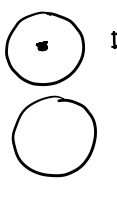

III : Clean Base ulcer.

low risk for Recurrance.

Mx : Active Bleeding : Hemo clips

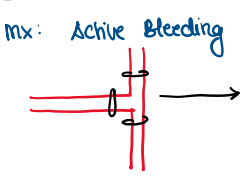

→ THREE POINT LIGATION of Gastro duodenal artery

✱ Perforation (Hollow viscus Perforation)
- m/c : Duodenal ulcer
- Anteriorly situated ulcer

C/F : Perforation Peritonitis

- ✱ Severe abdominal pain
- ✱ High grade fever
- ✱ Nausea & vomiting — paralytic ileus.
- ✱ Non passage of Stools & flatus.
- ✱ Abdominal Distention.

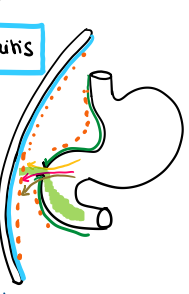

Contamination
1. Bile : most Irritant for Peritoneum.
2. Food substance
3. Blood
4. G.I secreations

O/E : ✱ Gaurding ⊕
- ✱ Cartboard Rigidity ⊕
- ✱ Bowel Sounds ⊖
- ✱ ↑HR, ↑RR, Hypotension

JOC : Erect X-Ray Abdomen → ⊕ free gas under Right Hemi diaphragm

BEST : CECT abdomen

Mx : Exploratory laprotomy
- Gastric ulcer → Biopsy from the Edge
  - ⊕ Adeno carcinoma → Mx as Gastric Carcinoma
  - Benign ulcer → Graham's omental patching
- Duodenal ulcer → Graham's omental patching

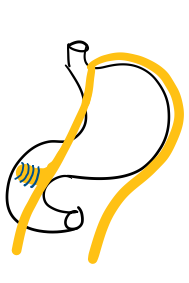

✱ Gastric outlet obstruction : m/c D1

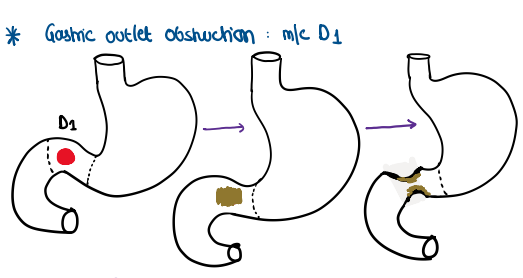

C/F ✱ Ⓡ Episodes of non Bilious vomiting

✱ Colicky Abdominal pain

1st INV : X-Ray
JOC : UGIE
mx : ✓- Heniken-mukilz pyloroplasty
- FENNY'S pyloroplasty

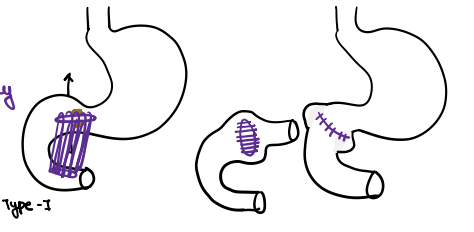

TEA POT STOMACH → TYPE-II
HOUR GLASS STOMACH : Type-I

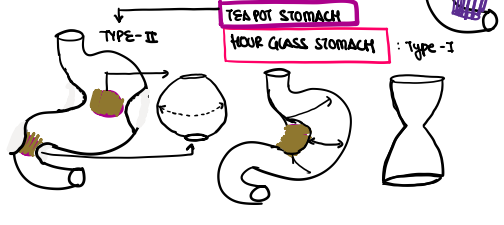

Complications a/w P.U.D SURGERY

- BILROTH Sx : II
  - Duodenal Stump Blow out : 4th P.O.D
  - pernecious anemia (B12 ↓ 2° to ↓CIF)
  - Dumping Syndrome
- VAGOTOMY
  - Truncal vagotomy
    - ✓ Cholelithiasis
    - ✓ Gastric paresis → Drainage procedure
    - ✓ ✗ hyposecreations.

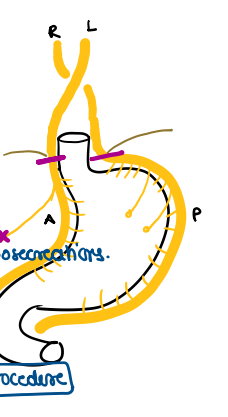

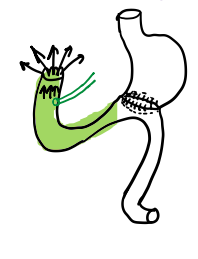

	Early	Late
	©: Rapid transit of food from stomach into jejunum	©: Rapid transit of food from stomach into jejunum
	Osmotic Diarrhoea DOC : Octreotide	Sugar Rich Bolus In jejunum → ↑↑ Insulin → Severe hypoglycemia
Time of Presentation :	<20-30mins	> 2hr
C/F :	Diarrhoea	Hypoglycemia
precipitating factor :	Food	Exercise
Relieving factor :	lie down supine	Food

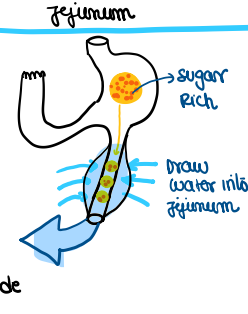
sugar Rich
Draw water into jejunum

Upper G.I Bleed

DIELAFOY'S GASTRIC LESION	G.A.V.E : Gastric Antral vascular Ectasia WATER MELON STOMACH
✗ Abnormal Arteriole of ~3mm ⓓ located 6-10cm from G.E.J on the lesser curvature of Stomach.	✳ Dilated vessels in the antrum of the Stomach.
C/F ✳ Hematemesis Ⓡ ✳ malena ⊕ ✳ hypotension	C/F ✳ AGE > 60yrs SEX : F>M - Anemia : Chronic Blood loss.
JOC : UGIE mx : Electro coagulation of the abn arteriole.	JOC : UGIE mx : UGIE ⟶ Electrocoagulation.

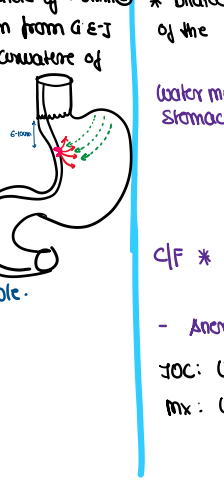

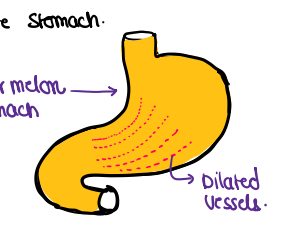
water melon stomach
Dilated vessels.

MENETRIERS DISEASE

✗ Hypertrophied mucosal folds in the Body and fundus of Stomach resulting in malabsorption.

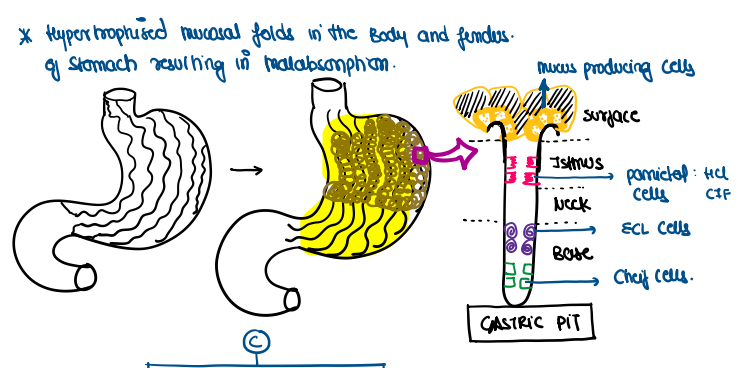
mucus producing cells
surface
Isthmus
parietal cells : HCl CIF
Neck
ECL Cells
Base
Chief cells.
GASTRIC PIT

©
- Idiopathic
- > Strong association
  - Adult → H.Pylori
  - Children → CMV

C/F : AGE : 40-50yrs
SEX : F>M

- ✳ Diarrhoea
- ✳ hypochloremia / hypochlorhydria
- ✳ pernicious Anemia : **PRE-MALIGNANT**
- ✳ hypergastrenemia
- ✳ hypoproteinemia : most chach. feature.
- ✳ Steatorrhea

JOC : UGIE
mx : prophylactic Total Gastrectomy

Carcinoma stomach

m/c/s : Around the Gastro Esophageal junction

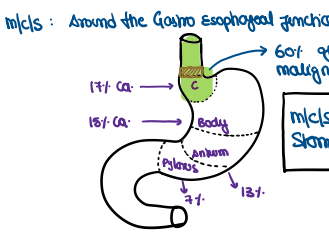
17% Ca.
15% Ca.
C
Body
Antrum
Pylorus
7%
13%
60% of Total malignancy.

m/c/s c̄ in the : Cardia Stomach

R/F ✳ NUTRITIONAL R/F :
- ↓ Fat diet
- ↓ protein diet
- salted meat
- High Nitrate Consumption

✳ Environmental R/F :
- Poor preparation of food : smoked
- smoking
- poor drinking water
- lack of refrigeration.

✗ medical R/F :
- Prior gastric Sx
- H.pylori : (Cag-A +ve) Heighest R/F Ca.
- Gastric Atrophy
- Type Ⓐ/Ⓑ gastritis (Ⓐ Autoimmune, Ⓑ H.Pylori)
- Adenomatous polyps.
- Males > Females.

Gastric Ca Genetics

1. E-CADHERIN : ↑ 80%
2. F.A.P
3. Duodenal polyp : very high malignant potential
4. p53 mutation
5. HNPCC
6. p16

WHO classn : Carcinoma stomach

- Adeno.ca (m/c)
  - papillary (Good)
  - Tubular
  - mucinous
  - Signet ring (WORST prognosis.)
  - mixed
- Adeno squamous
- Squamous ca.
- Undiff
- Unclassified

LAUREN classn : Gastric ca

	Intestinal Type	Diffuse Type
Sex	M	F
AGE	> 50yrs / R/F ↑ c̄ ↑ Age	young (30-40ys)
Genetic	Sporadic	familial
Genes	APC, P53, P16	E-Cadherin, P53, P16
R/F	Gastric Atrophy Intestinal metaplasia	Blood group 'A'
mode of spread	Blood	Direct & lymph
H.P.E	- Gland forming - MSI	Signet ring
Prognosis	Good	Poor

C/F : Silent.Ca (slow growth)
- ✳ Dysphagia : Solids > liq progressive
- ✳ Dyspepsia ⊕
- ✳ Early satiety
- ✳ Gastric outlet obstruction
- ✳ - Hematemesis
  - malena
  - Anemia
- ✗ vauge Epigastric dyscomfort

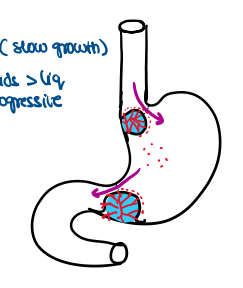

Q.
m/c clinical presentation : Abdominal pain > weight loss.

ATYPICAL PRESENTATION

1. Enlarged lymph nodes
   - Ⓛ supra clavicular :- Virchow L.N (TROSSIER Sign)
   - Ⓛ Axilla : Irish L.N
   - peri umblical : Sister mary Joseph L.N
2. migratory superficial Thrombophlebitis : (TROSSUE Syndrome)
3. pelvic metastasis : Per rectal ⟶ ⊕ Blummer self.
4. Ovary tumour : 2° to Drop metastasis / Trans peritoneal spread
   KRUKENBERG TUMOUR

JOC : UGIE + Bx

morphology

Q.

Early Ca. (Japanese classn)		Advanced Ca (Borrman's classn)	
Type I :	PROTRUDED	Type I :	Polyploidal
Type IIa	Flat & sup. Elevated	Type II :	Ulcer c̄ Elevated margin.
Type IIb	Flat	Type III :	Ulcer c̄ infiltration into gastric wall.
Type IIc	Depressed.	Type IV :	Linnitis plastica : a/w worst prognosis
Type III	Excavated.	Type V :	Non classifiable.

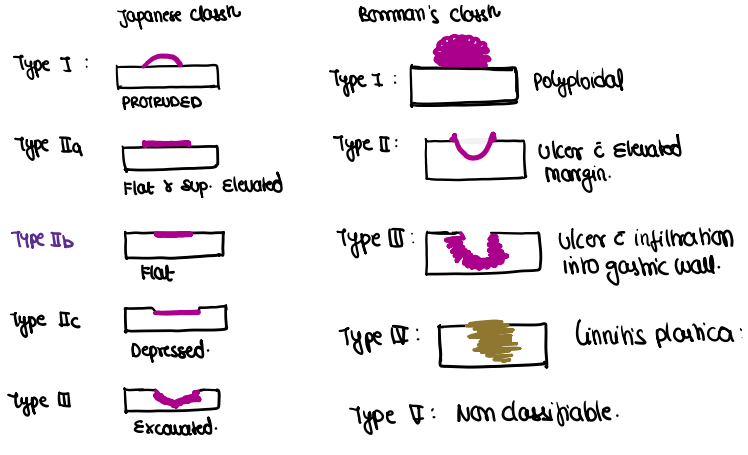

TNM - classification

T1a :	⊕ lamina Propria	N0		M0 :	✗
T1b :	⊕ Sub mucosa	N1 :	1-2 regional L.N ⊕	M1 :	✓
T2 :	⊕ muscularis propria	N2 :	3-6 " "		
T3 :	⊕ Sub serosa	N3a :	7-15 " "		
T4a :	Tumour perforates Serosa	N3b :	> 15 " "		
T4b :	Tumour invading adjacent organs.				

mx
- Operable Tumour → ≤T3, N1, N2
- Inoperable Tumour → ≥ T4 or N3 or M1 → palliative mx
  - Feeding jejunostomy
  - Endo G.I stenting

proximal ⅓ : Extended gastrectomy + D2
middle ⅓ : Total gastrectomy + D2
Distal ⅓ : Sub-Total gastrectomy + D2

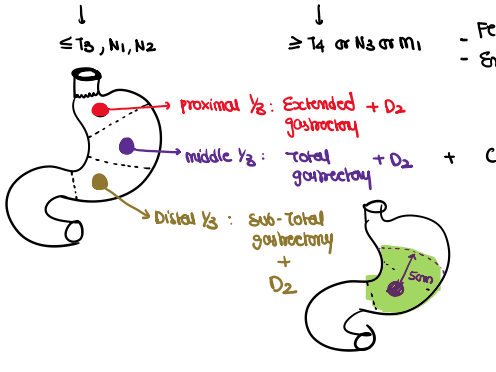

+ Chemo :
- E : Epirubicin
- C : Cisplatin
- F : 5FU

Gastro Intestinal Stromal Tumour

G.I.S.T

- ✳ m/c mesenchymal tumour of G.I.T
- ✳ m/c/s for G.I.S.T : Stomach

Genetics of G.I.S.T

Tumour markers
- ✳ over Expression of Tyrosine kinase Receptor (C-kit)
- ✗ CD117
- ✗ CD34
- ✗ BCL-2

New Tumour marker ✳ DOG-1

Origin : Interstitial cells of CAJAL

C/F ✗ Upper G.I Bleeding
m/c Clinical presentation of G.I.S.T
- m/c/s for 2° : liver
- lymph nodes are usually spared in G.I.S.T

CARNEY'S TRIAD

- pulmonary Chondroma
- Extra Adrenal paraganglioma
- multi focal G.I.S.T

1st INV : UGIE
JOC : CECT

FLETCHER'S classn

Benign

	Size	mitosis / 50HPF
1. Benign	<2cm	<5
2. Probably Benign	2-5cm	<5

malignant

	Size	mitosis / 50HPF
low	<2cm	>5
mod.	2-5cm <10cm	>5 <5
High	>5cm	>5

mx
- Benign → Wedge shaped Excision
- malignant
  - Resectable Tumour → Resection & anastamosis (margin : 5cm)
  - Unresectable Tumour → Imatinib → RESISTANCE → SUNITINB

✓ Joc for Assessment of Recurrance : PET-scan.

Polyps

- Inflammatory
  - (pseudo polyps)
  - (2° to U.C)
  - least R/F malig. Transformation
- Hyperplastic polyp
- Adenomatous polyp
  - max. malig. Potential
- Hamartomatous polyp.
  - JUVENILE Polyps : young Pt

PEUTZ-JEGHER Syndrome : GENE : STK-11 LKB-1
- ✳ Polyposis (multiple polyps) + Pigmentation (muco cutaneous)
- ✗ m/c/s for Polyps : Jejunum
- ✳ m/c type of polyp : Hamartamatous Polyp.
- ✳ ↑ R/F Ca : PANCREATIC.CA, PERI AMPULLARY.CA, COLO RECTAL.CA, THYROID.CA, DUODENAL Adeno.Ca

Adenomatous Polyps

- TUBULAR Polyp
- TUBULOVILLOUS polyp
- Villous polyp (max. R/F malignancy.)



- Pedunculated polyp
- Sessile polyp

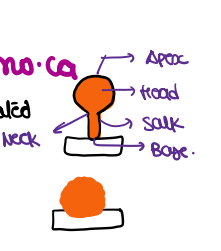
Apex
Head
Stalk
Neck
Base.

HAGGIT CLASSIFICATION

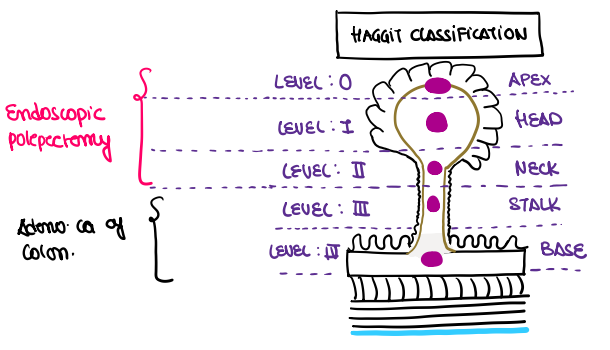
Endoscopic polepectomy
LEVEL : 0
APEX
LEVEL : I
HEAD
LEVEL : II
NECK
LEVEL : III
STALK
Adeno ca of Colon.
LEVEL : IV
BASE

Polyposis

multiple polyps.

Familial Adenomatous Polyposis : F.A.P

- * Chr. 5
- * Gene : APC
- * polyposis : min. no. of polys req > 100
  Attenuated FAP : < 100 polyps
- * A.D
- * 100% R/F malignant transformation.

Pt. c̄ FAP

↓

- Total proctol Colectectomy c̄ ileo- Anal Anastamosis (J-pouch)

Screen all family members

R/F malignancy ↑↑ > 40yrs

- Colonoscopy
- mutation

⊕ → Prophylactic Total proctol Colectomy

⊖

Hereditory Non polyposis Colorectal. Ca

H.N.P.C.C

* Genetic mutation : DNA mismatch Repair Gene
  Gene : HSH2 | MLH-1 : m/c

LYNCH

LYNCH-1

↑ R/F : Colorectal. ca

LYNCH-1

↑ R/F :
- UTERINE. ca
- Ovarian. ca
- Gastric. ca

HNPCC : Amsterdam Criteria (modified)

1. Rule out F.A.P
2. Atleast 3 family members ⊕
3. Atleast 2 successive generation ⊕
4. Atleast 1 1st Degree relative ⊕
5. Atleast 1 should be diagnosed < 50yrs.

GARDNER SYNDROME

1. FAP
2. Osteoma : maxilla/mandible
3. Fibroma
4. Epidermal cyst
5. Desmoid tumour
6. Congenital Hypertrophy of Retinal pigment Epithelium.

TURCOT Syndrome

- FAP + Brain tumours

COLO RECTAL - Cancer

m/c type : Adeno. Ca
m/c/s : Recto sigmoid.

R/F
- * High fat intake c̄ low fiber diet
- * Red meat
- * I.B.D (UC > CD)
- * Diverticular disease
- * Adenomatous polyp
- * FAP, HNPCC, TURCOT synd, Gardner synd
- * Ureteo sigmoid anastamosis
- * H/o pelvic radiation

Colorectal. Ca

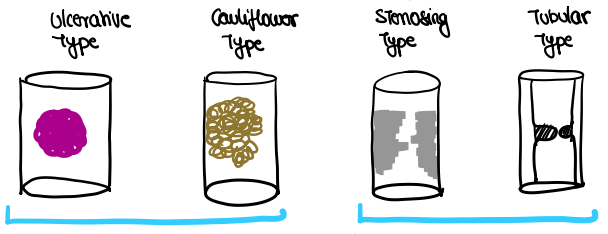
Ulcerative Type
Cauliflower Type
Stenosing Type
Tubular Type
m/c Right
m/c : Left

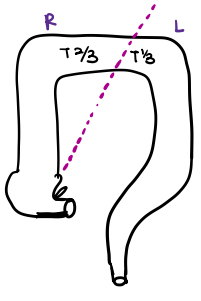

C/F

Right sided. ca	Left sided. ca
* malena] m/c * Anemia] * Hematochezia : Rare * R.I.F mass : palpable * S/s of small Bowel #	* large Bowel dynamic obstruction * Alteration in Bowel habbits. * Early morning spurious diarrhoea * Tenesmus * ⊕ Blood & mucus in stools * Hematochezia

IOC : Colonoscopic Biopsy
IOC for staging : PET-CT
IOC for 'T' & 'N' Determination : MRI c̄ Endorectal coil

TNM- classn

T_1 : ⊕ submucosa
T_2 : ⊕ muscular layer
T_3 : ⊕ perimuscular connective tissue
T_{4a} : > serosa (perforated)
T_{4b} : ⊕ adjacent organ

N_1 : 1-3 Regional L.N ⊕
N_2 : ≥ 4 " "

m_0 : ×
m_1 : ✓

DUKES STAGING

A : limited to mucosa & submucosa
B_1 : B/w muscular layer & serosa
B_2 : serosal perforation
C_1 : B_1 + L.N
C_2 : B_2 + L.N
D : Distant metastasis : m/c route of spread : Blood
m/c site for 2° : liver

- small
- peripheral
- multiple
- hypovascular.

(Mx) : Margin : 5cm.

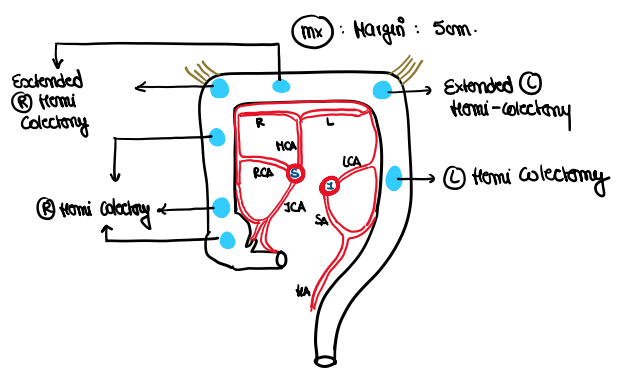
Extended R Hemi Colectomy
R Hemi colectomy
Extended L Hemi-colectomy
L Hemi colectomy
R
L
MCA
RCA
LCA
JCA
SA
IMA

Right Hemi colectomy

"Radical"

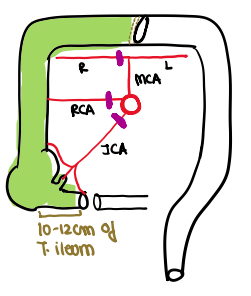
R
L
MCA
RCA
JCA
10-12cm of T. ileum

Ileo transverse anastomosis

Extended R Hemi colectomy

"Radical"

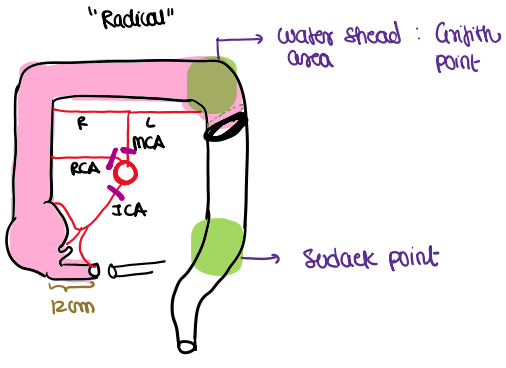
water shead area : Griffith point
R
L
MCA
RCA
JCA
Sudeck point
12cm

Left Hemi Colectomy

Radical

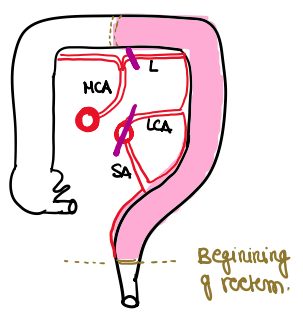
L
MCA
LCA
SA
Begining of rectum.

Extended L Hemi Colectomy

"Radical"

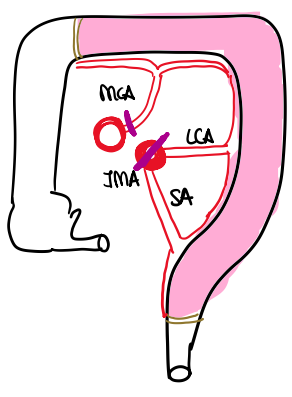
MCA
LCA
IMA
SA

(Mx) : Rectal. Ca

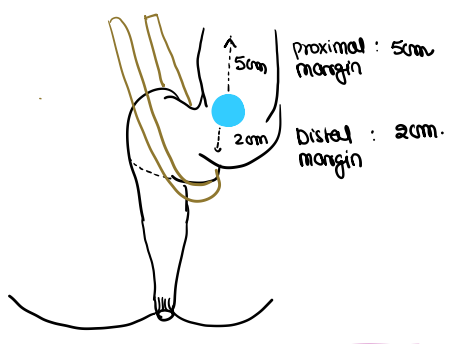
5cm
2cm
proximal margin : 5cm
Distal margin : 2cm.

Criteria for local Resection in Rectal. ca

- * T_1N_0 or T_2N_0
- * < 4cm in diameter
- * < 40% of Circumference of rectum
- * < 10cm from dentate line
- * well to mod. diff tumour.
- * lympho vascular spread ⊖

Distal margin

Adequate

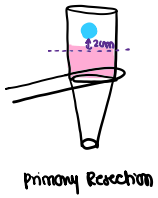

Primary Resection and anastamosis
- low anterior Resection
- T.A.M.S (Trans anal mesorectal Excision Sx)
- T.M.E Total mesorectal Excision.

Inadequate → A.P.R (Abdomino perineal) Resection

CHEMOTHERAPY

- ⊕ lymp Node metastasis
- T3 / T4

↓

FOLFOX : 5FU + OXALIPLATIN + Folinic acid
FOLFIRI : 5FU + Folinic acid + IRINOTECAN
CAPECITABINE + OXALIPLATIN.

Radio Rx : only for Rectal. ca.