



## Structure

- parenchyma (duct & secretory <sup>→ lobule</sup> acini)
- connective tissue stroma
- adipose tissue
- blood vessels & lymphatics

lobule → milk produced

duct → stored

- 15-20 lobules
- each lobule has separate lactiferous duct
- Lactiferous duct converge toward nipple in radiating manner.
- distal end of
- connective tissue - spiracular thickened part - suspensory ligament of Cooper
- helps in anchorage
- connects base to pectoral fascia of skin

## Arterial Supply

1. Axillary Artery
2. Subclavian artery - internal mammary artery
3. Posterior intercostal artery

## Venous drainage of Breast

- Veins radiate from areola - circular venous plexus
- Superficial veins - drain into internal thoracic.

- cancer cell from breast



- posterior intercostal vein



- vert. vertebral venous plexus



- get lodged in vertebrae



enter cranial dural venous sinus



Brain

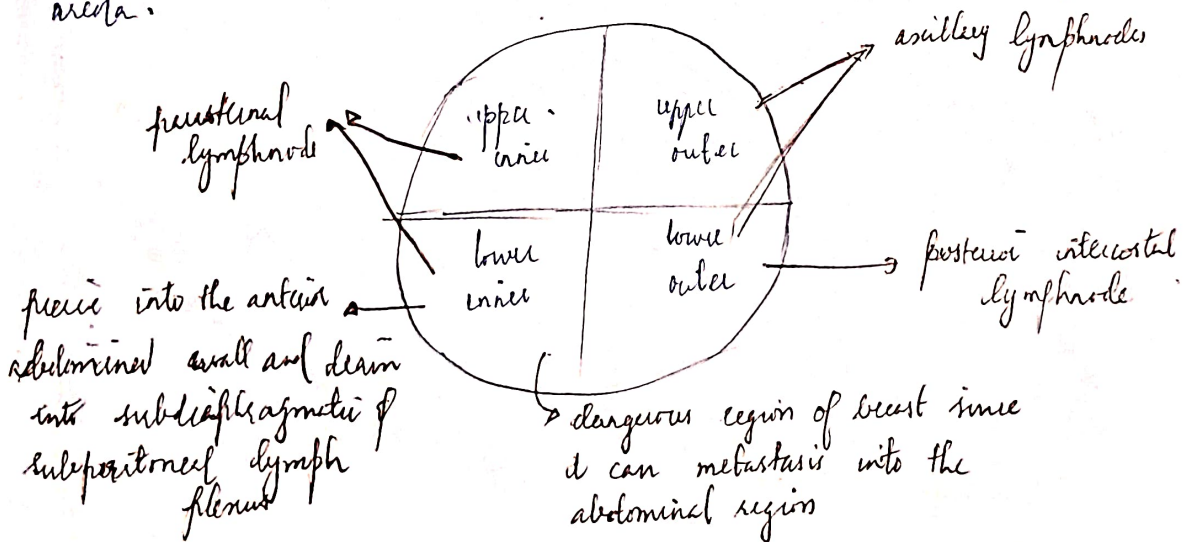
Nerve supply  $\rightarrow$  somatosensory supply  $\rightarrow$  parietal lobe of brain

- Intercostal nerve through 2<sup>nd</sup> to 6<sup>th</sup> intercostal anterior & lateral cutaneous branches.

### Lymphatic Drainage of Breast

- Axillary lymph node 75%
  - Parasternal lymph node 20%
  - Posterior intercostal lymph nodes 5%
- $\rightarrow$  Deltopectoral

Superficial lymphatics - drains the skin over the breast except the nipple and areola.



⇒ The lymph from the deep surface of breast - passes the pectoralis major muscle of clavipectoral fascia.

Subareolar plexus of Sappey - The plexus of lymph vessels deep into the areola

⇒ The parasternal lymphnodes of both sides are interconnected.

⇒ The lymphatics from one parasternal lymphnode

Sentinel lymphnode :-

first lymphnode or group of nodes draining a cancer.

Sentinel lymphnode of breast - Axillary lymphnode

- Anterior

Polyphelei -

Polymastie  
amastie

Gynecomastie - development of breast in males

Carcinoma of Breast

- most common cancer in females.
- 60% - upper lateral quadrant
- age - 40-60 years

retraction of skin  $\rightarrow$  suspensory ligament

Krukenberg Tumor  $\rightarrow$  ovary gets deranged with tumor