

Superficial palmar arch ✓ 7+

Location → palm. → distal part
↓ corresponds to
distal palmar crease.

Formation → on medial side of palm as
continuation of ulnar artery

Course → runs laterally, with convexity
towards digits.

Anastomosis → joins one of :

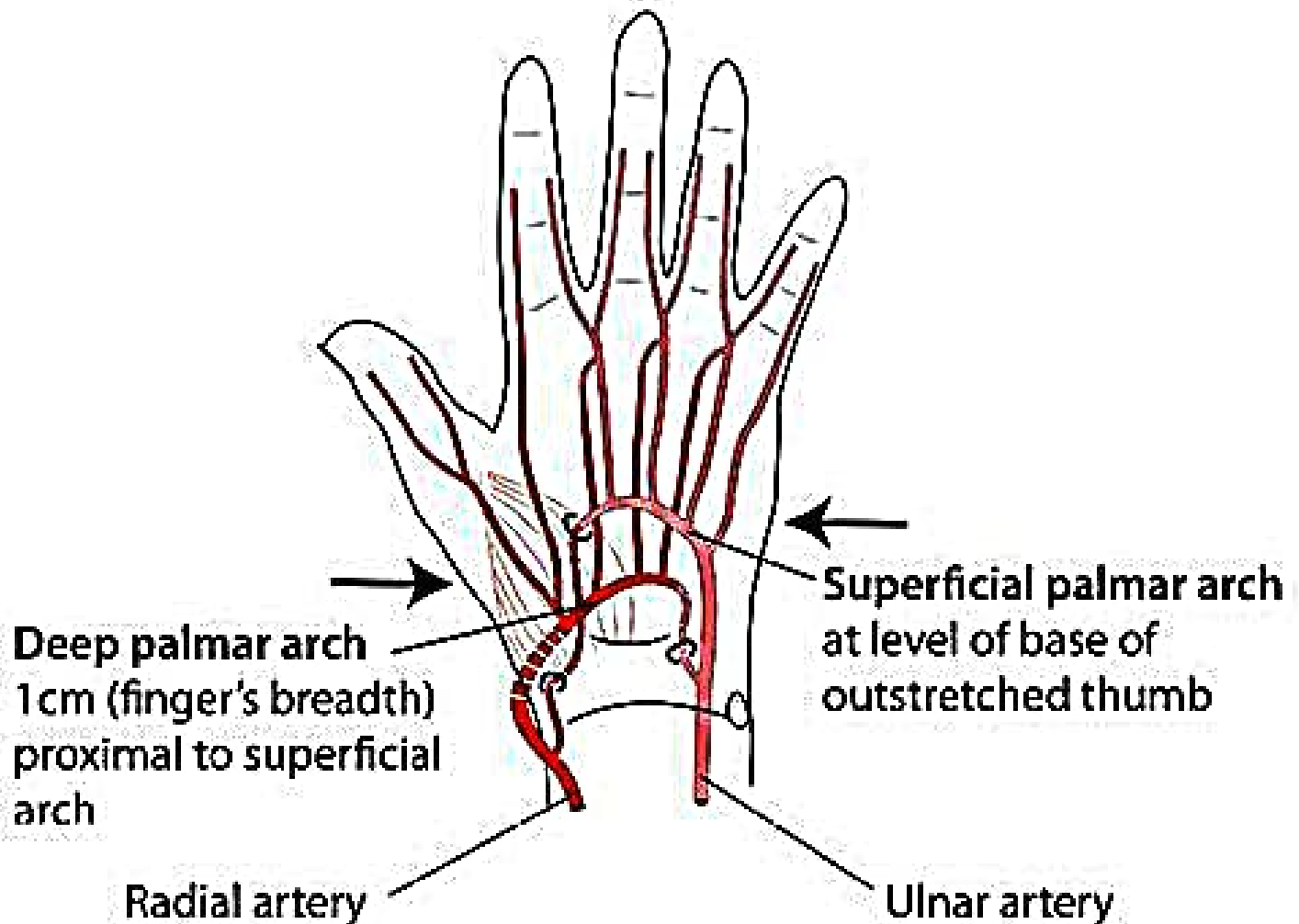
- superficial palmar branch of R.A.
- radialis pollicis
- princeps pollicis

Relations

Anterior - palmar aponeurosis

Post → FDS, FDP (lateral), lumbricals.

PALMAR ARTERIAL ARCHES. Left hand



Radial artery gives
deep palmar arch with
connections from the
ulnar artery

Ulnar artery gives
superficial palmar
arch with a connection
from the radial artery

**Allen's Test: Provides information
as to which arch is dominant**