

## Serratus anterior (Boxer's muscle)

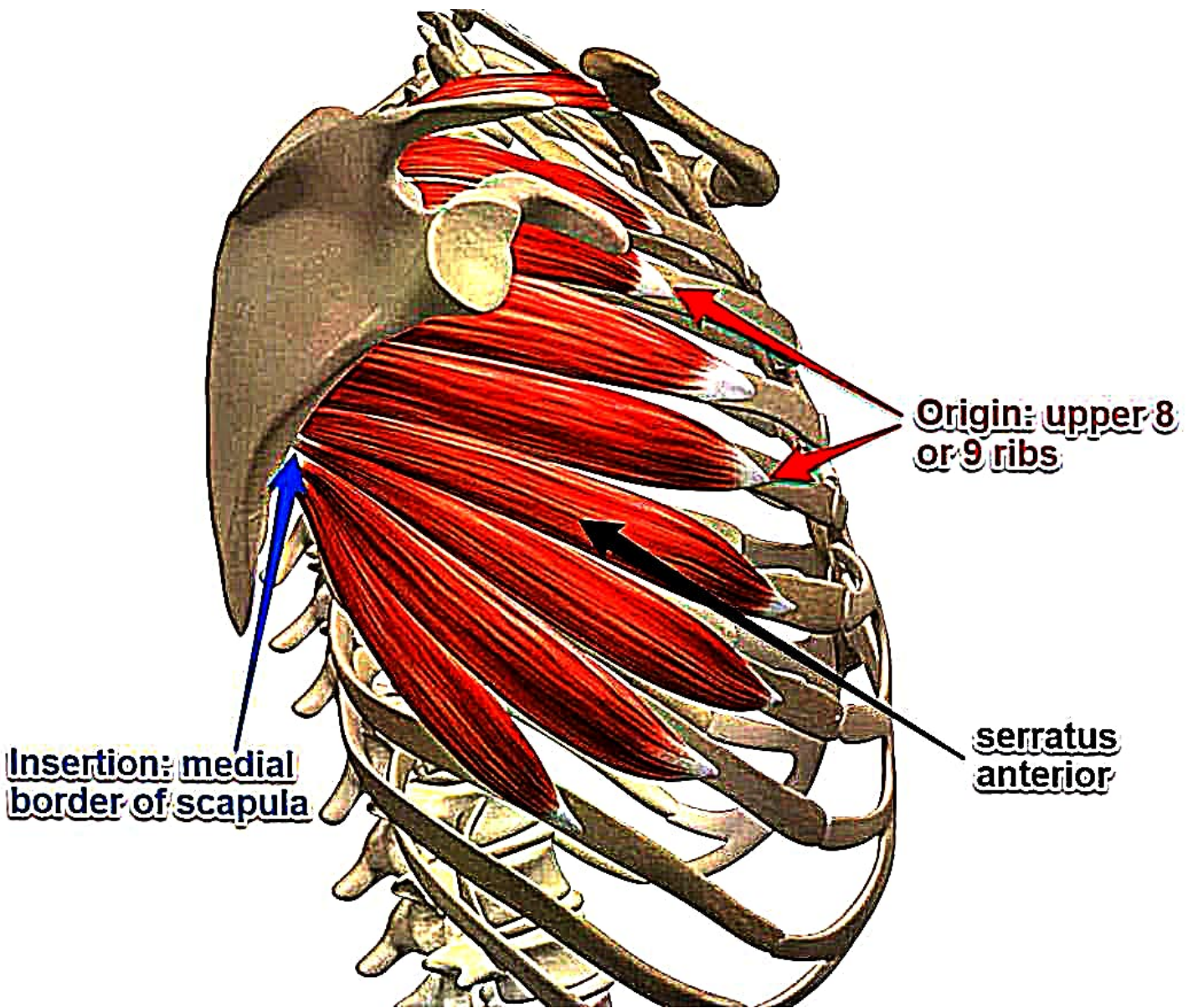
large muscle that clothes lateral side wall of upper thorax.

### Origin.

8 digitations from 8 upper ribs.

first digitation from both 1<sup>st</sup> & 2<sup>nd</sup> ribs,

remaining digitations from respective rib.



## Insertion

- medical border of costal surface of scapula.
- superior angle: 1<sup>st</sup> digitation
  - medial border: rest 2.
  - inferior angle: remaining 5.

Nerve: long thoracic nerve /  
nerve of bell.

action: protraction of scapula:  
with pectoralis minor.

→ punching motion

→ **Boxer's muscle**

## Applied. Anatomy

- paralysis of SA due to injury to nerve of bell [long & superficial]

→ Winging of Scapula.

pushed against resistance,

medial & inferior border of scapula

becomes prominent.