

Short notes.

1.

Pectoralis major.

- It is a large, powerful fan shaped muscle, and largest in the pectoral region. forms anterior axillary fold!

ORIGIN:


2 heads of origin.

CLAVICULAR HEAD:

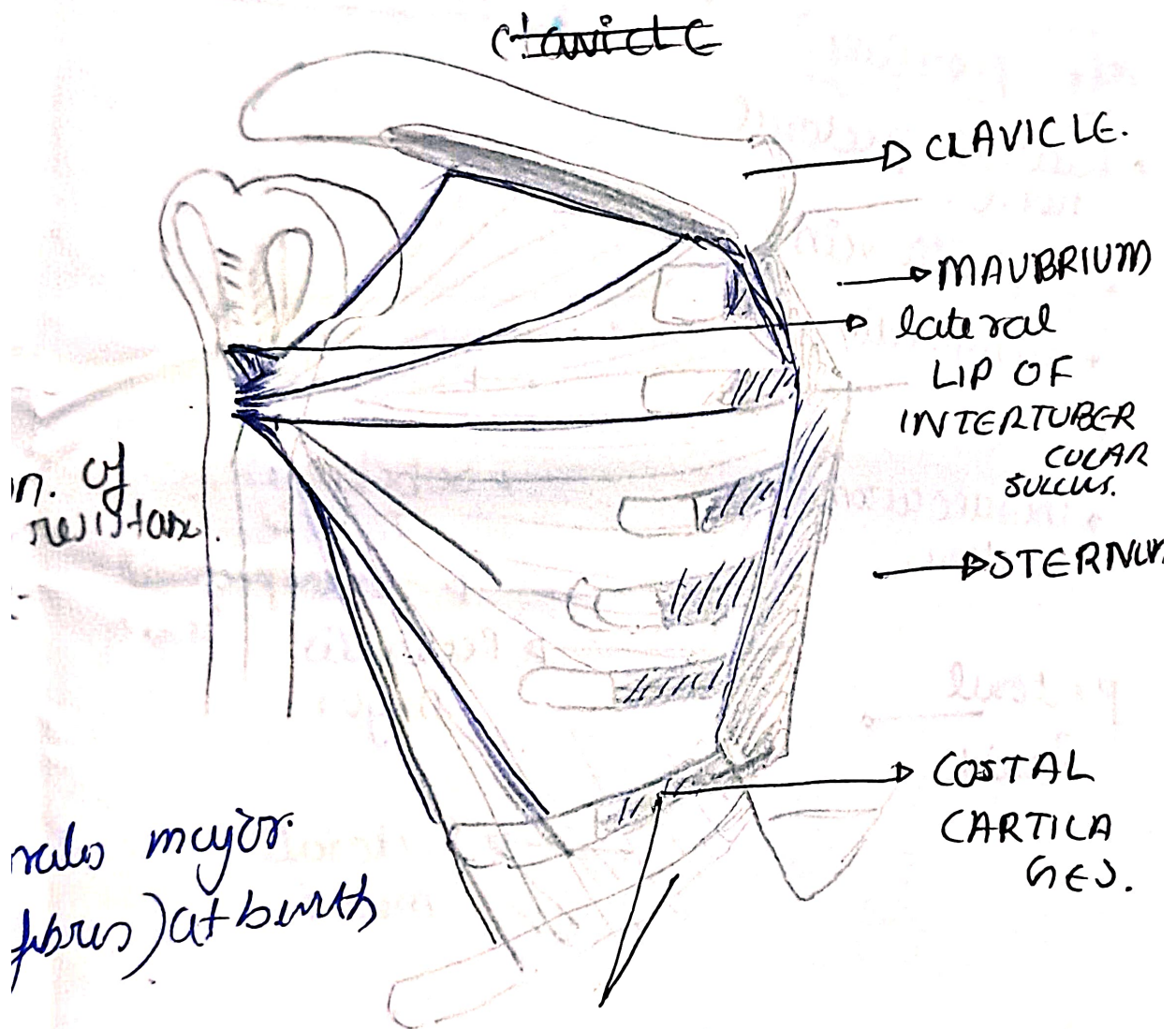
anterior surface of
medial 2-3rd of
clavicle.

STERNOCOSTAL HEAD:

- ~~lateral~~ half of anterior surface of sternum. upto 6th costal cartilages
- 2nd - 6th costal cartilage.
- aponeurosis of external oblique muscle.



Lateral lip of
a U shape due to
rounded anterior axillary fold.



curvature.

- Aponeurosis of muscle.

INSERTION.

- Inserts as a bilaminar tendon on the lateral lip of bicipital groove of humerus, forming a U shape due to twisting of posterior lamina. forms rounded anterior

NERVE SUPPLY.

medial & lateral pectoral nerve.

↓
C5 - C7

↓
C8 & T1.

ACTION.

as a whole: adduction & medial rotation of humerus against resistance.

clavicular: Flexion against resistance

sternocostal: extension. "

Poland syndrome: absence of pectoralis major (sternocostal fibres) at birth

↓
absence of pectoralis major & minor.

Breast hypoplasia.

2-4 rib segments absent

