

BONY ORBIT.

- pyramidal shaped cavities.
- provide sockets for rotation of eyes

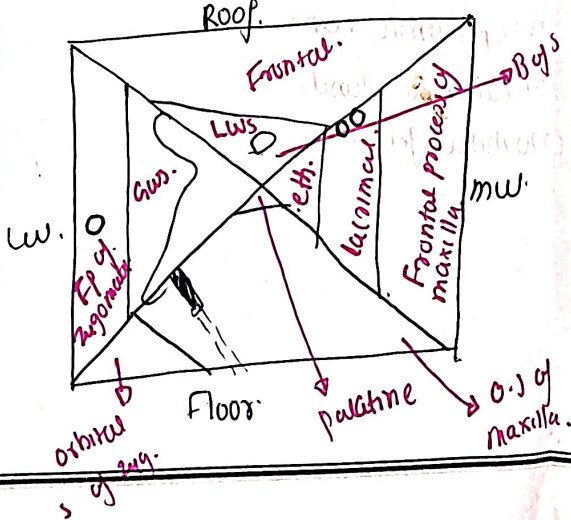
BOUNDARIES.

- medial wall = ① frontal process of maxilla.
- ② lacrimal process of maxilla.
- ③ orbital plate of ethmoid.
- ④ Body of sphenoid.

- Lateral wall: ① Orbital surface of zygomatic in front
- ② orbital surface of greater wing of sphenoid.

- Floor: Orbital surface of maxilla.
- Orbital surface of zygomatic.
- Orbital process of palatine.

- Roof: orbital plate of frontal bone.
- lesser wing of sphenoid.



Features.

medial wall.

- (1) lacrimal fossa.
 - anterior -> lacrimal crest of maxilla
 - post lacrimal crest of ~~superior~~ lacrimal bone.
- communicates with nasal cavity -> nasolacrimal canal.
- lacrimal sac -> lacrimal fovea
- nasolacrimal -> nasolacrimal duct. canal
- (2) ant & post ethmoidal foramina. -> @ jnt of med wall & floor.

Lateral wall

- (1) zygomatic foramen.
 - some 2 for zygomatic facial & zygomatic maxillary bone.
- (2) Whitnall's tubercle.
 - > below frontozyg suture & behind lateral orbital margin.

Floor:

- infra-orbital groove, & canal
- origin of inferior oblique muscle.

Roof

- lacrimal fossa
- optic canal
- trochlear notch / supra-orbital notch!

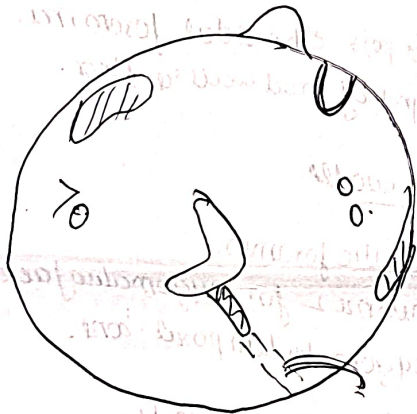
Margins.

• supraorbital → frontal bone.
 • supraorbital notch at
 jxn of Lat 2/3 & med 1/3.

infraorbital → zygomatic & maxilla.

lateral → zygomatic process of F
 & FP of zygomatic

med → frontal bone
 (lateral crest of) frontal
 process of maxilla.



Relationship:

above → frontal crest, &
 Anterior cranial fossa.

medial → Ethmoidal air sinus.

below → Maxillary air sinus.

lateral → Temporal fossa (front)
 middle cranial fossa (behind)

Orbital fascia / peri-orbita.

- pericoteum of bony orbit forms funnel shaped fascia.
- It is loosely attached.

@ optical canal & superior orbital fissure.

→ It becomes continuous with endocranium. (Perosteum covering int of skull)

@ Infraorbital fissure & orbital margin. It becomes continuous with perosteum covering external surface of skull.

Contents

- (1) eye ball.
- (2) muscle.
- (3) fascia bulbi
- (4) Nerves.
 - Optic
 - Oculomotor
 - Trochlear
 - Abducent
 - Ophthalmic
 - ciliary ganglion.
- (5) ophthalmic artery.
- (6) ophthalmic vein
- (7) lacrimal gland
- (8) orbital fat.

