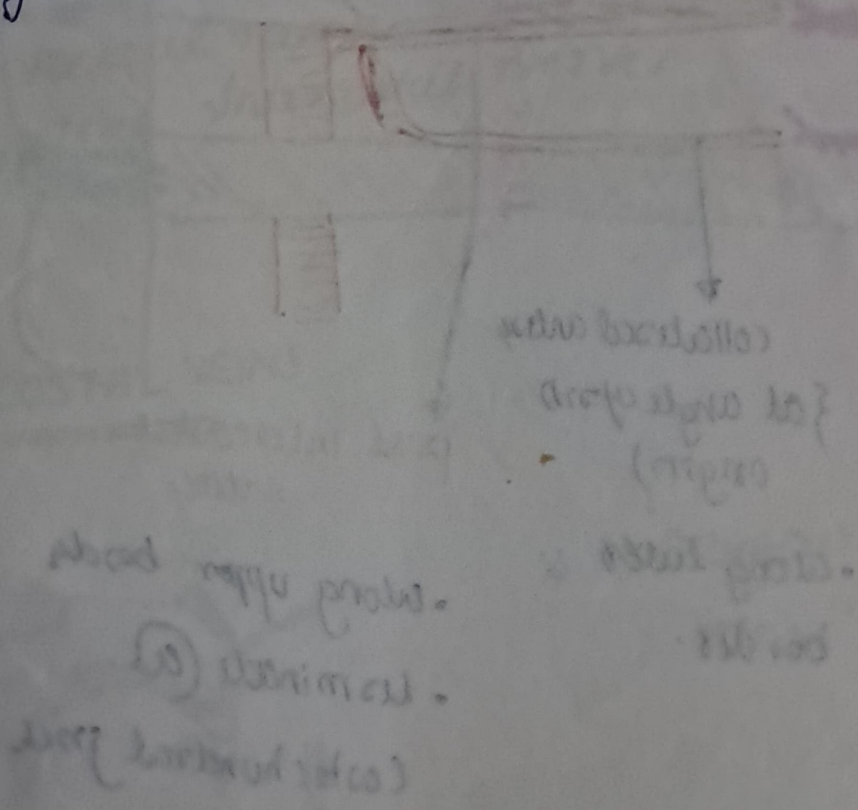


Bucket handle movement } occurs together in normal
pump handle movement } expiration/inspiration.

Intercostal artery.

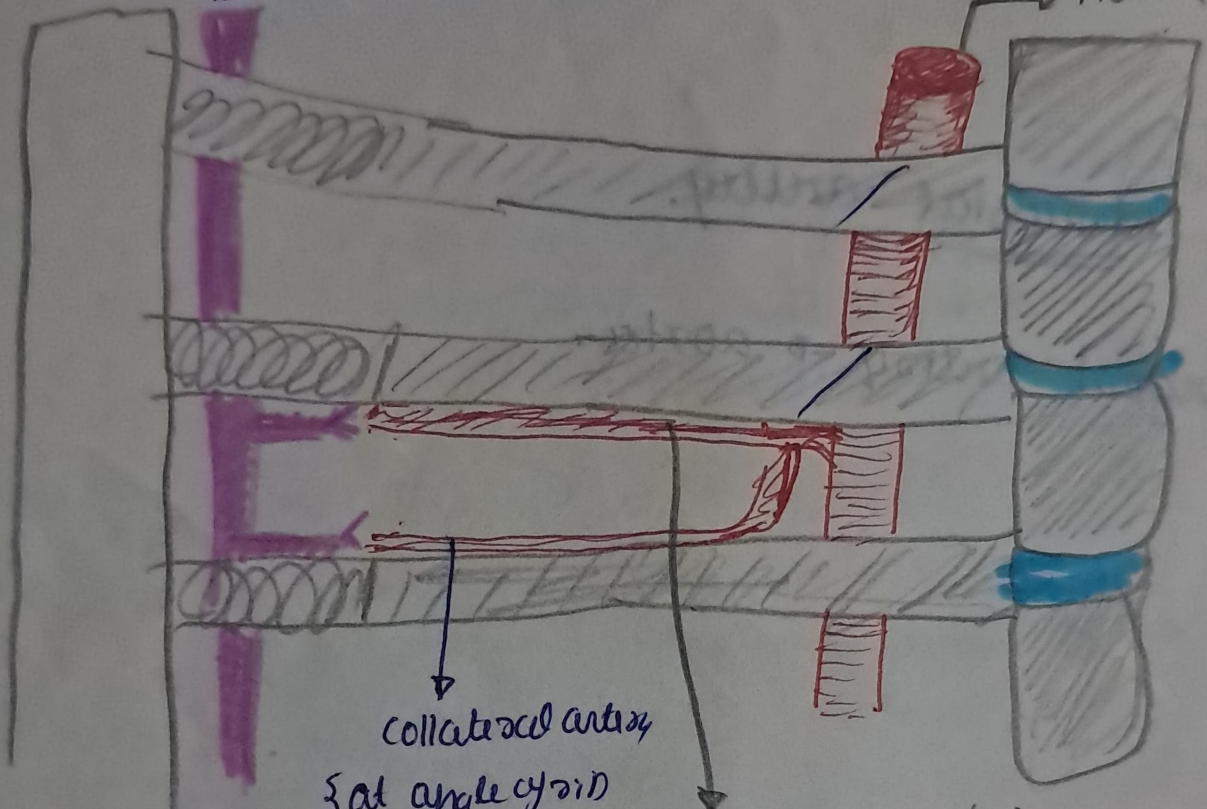
- Largest artery → aorta.



lyft

Internal thoracic artery.

Aorta



collateral arteries

(at angle of origin)

- along lower border.

post intercostal arteries

- along upper border
- terminate @ Costochondral jct.

* 1st pair of intercostal arteries → start
* Internal thoracic artery: for bypass.

↓ ends by dividing into.
* → bronchophrenic artery.
* → superior epigastric artery.

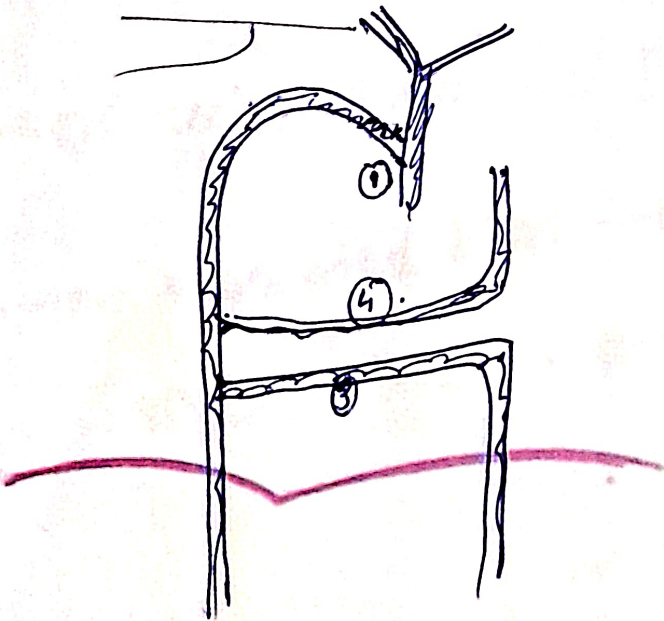
} @ 6th. ^{intercostal} ~~sub.~~ space.

• INTERCOSTAL NERVE.

- from ventral rami!
- 1-6 - typical intercostal nerves

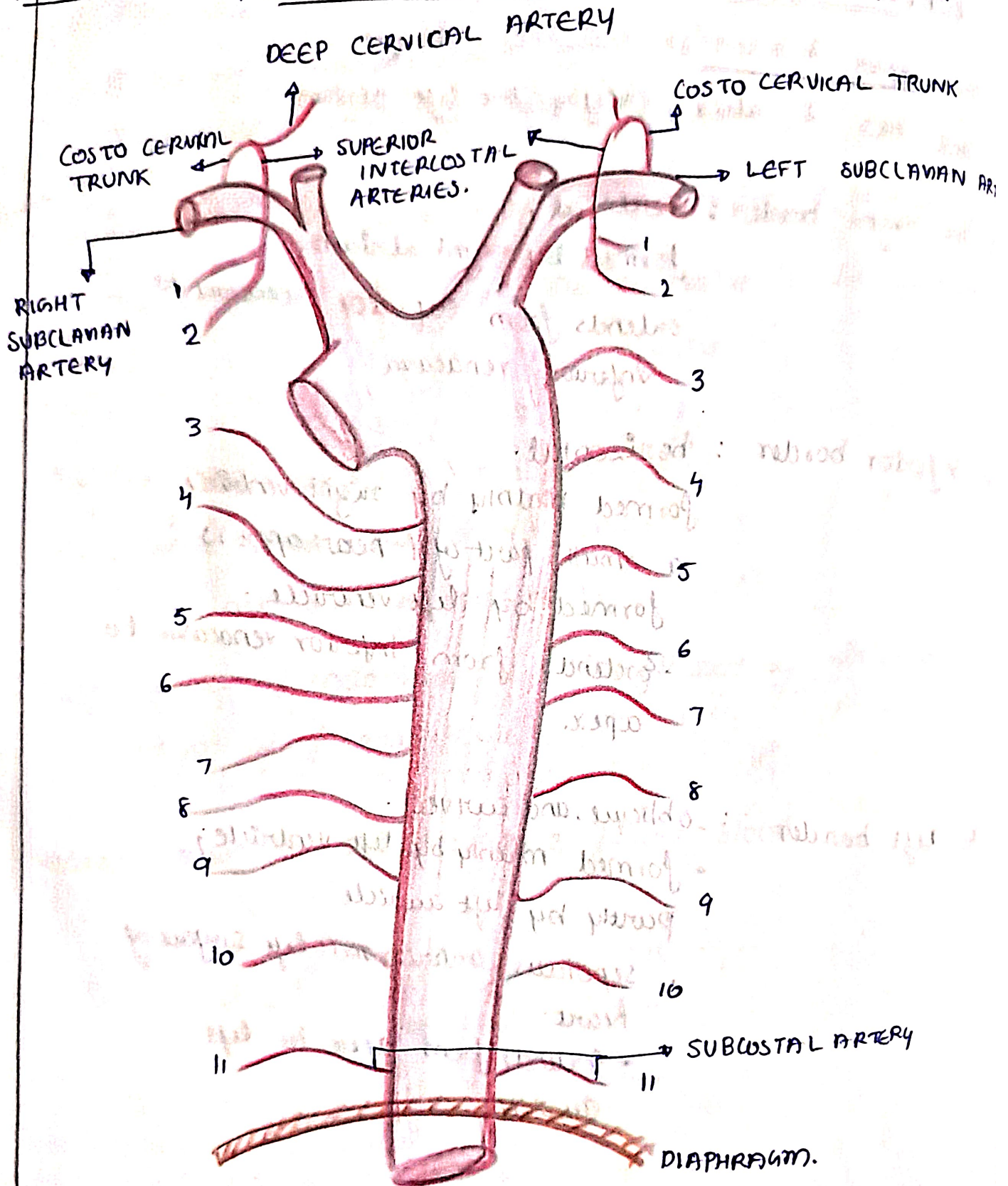
INTERCOSTAL VEINS.

* azygos system of veins.



16/11/2023

POSTERIOR INTERCOSTAL ARTERY.



16/11/2023.

POSTERIOR INTERCOSTAL VEINS.

