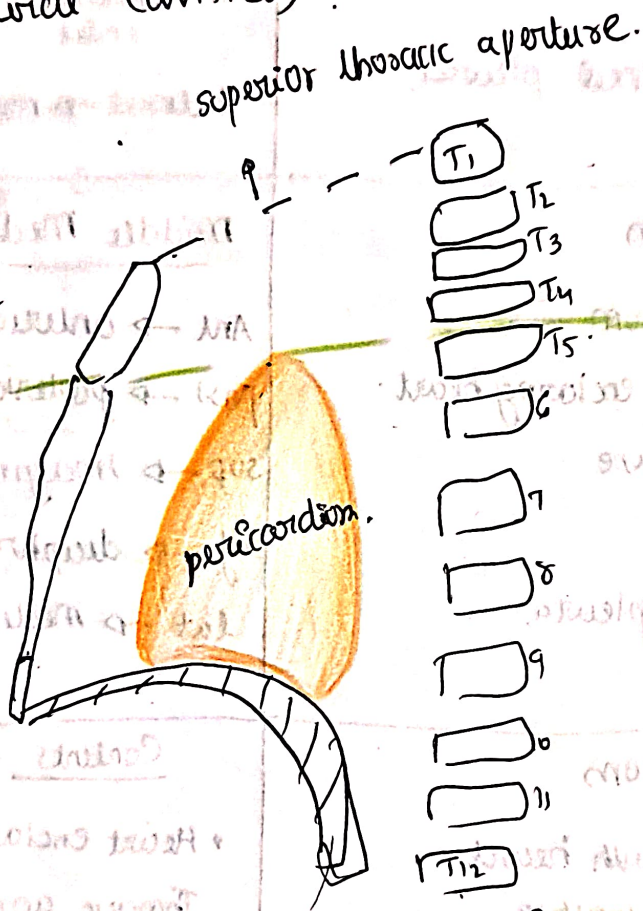


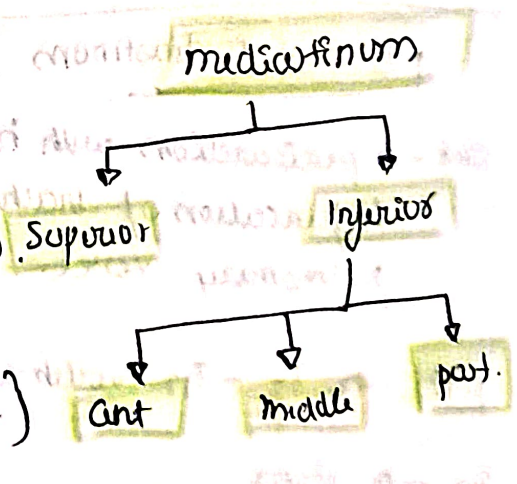
# Mediastinum

- Median mobile septum of thoracic cavity that ~~contains~~ ~~at~~ ~~major~~ is present btw two lungs. (two pleural cavities)



Imaginary plane passing through sternal angle in front & T4 & T5 intervertebral disc behind.

{ by imaginary plane }



{ by pericardium }

→ Boundaries can be said from this figure easily.

## mediastinum

Ant → Sternum      Post → Thoracic vertebrae.  
Sup → superior thoracic aperture      Inf → diaphragm.  
lateral → mediastinal pleura.

## Superior mediastinum

ant - manubrium      post → v. cava  
Sup → superior thoracic inlet      Inf → transverse plane.  
lateral → mediastinal pleura

## Anterior Mediastinum

- ant → body of sternum
- post → pericardium enclosing heart.
- sup → imaginary plane
- inf → diaphragm.
- lat → mediastinal pleura.

## Middle Mediastinum

Ant → anterior mediastinum  
post → posterior mediastinum  
sup → imaginary plane.  
inf → diaphragm.  
lat → mediastinal pleura

## posterior mediastinum

ant → pericardium with heart  
bifurcation of trachea,  
pulmonary vessel.

post → T5 - T12 vertebrae.

sup → plane

inf → diaphragm.

side → mediastinal pleura

## Contents - Mediastinum.

- Heart enclosed in pericardium
- Thoracic aorta
- pulmonary trunk
- Trachea
- Oesophagus.
- Thoracic duct
- Thyroid
- Sympathetic trunk,  
vagus, phrenic
- Lymph nodes.

# LUNG

## Internal structure

mainly made of.

- ↳ Bronchial tree {conduction of air}
- ↳ pulmonary units {gaseous exchange}

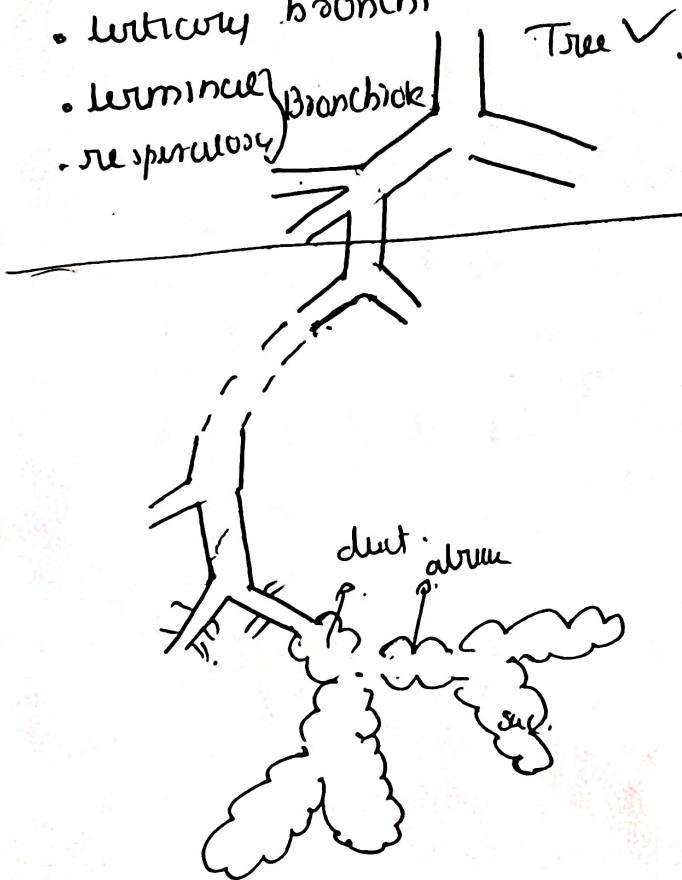
## Bronchial tree

- principle bronchi → right
- lobar bronchi (R-3) (L-2),
- tertiary bronchi.
- terminal bronchioles
- respiratory bronchioles

or left. {differences}

pulmonary unit

components?



## Arterial supply

- (1) Bronchial artery
- (2) pulmonary artery

## venous drainage

- (1) Bronchial veins
- (2) pulmonary vein

number in each lung?

derived from? or drain into?


# Lymphatic drainage

Imp  
metastasis of lung cancer

① Superficial lymph vessels → drains peripheral lung tissue



form superficial pleura  
between visceral pleura.



drain into

bronchopulmonary / hilum lymph nodes. → { same as below }

drains

② Deep lymph vessels → Bronchial tree, pulmonary vessel.



form deep pleura.



pulmonary lymph nodes { within lung substance }



Bronchopulmonary (hilum) lymph nodes.



Superior & inferior bronchobronchial ly. N.

{ above & below  
bifurcation of bronchus }



pre & paratracheal lymph nodes



mediastinal lymph trunk. → right  
lymphatic duct.

Left  
thoracic duct

## Nerve supply.

para & sympathetic  
↓  
from vagus

↳ from  
T<sub>2</sub>-T<sub>5</sub> spinal  
segments.

Both

→ motor supply to bronchial muscle  
secretomotor supply to  
mucous gland.

• parasympathetic → bronchoconstriction.  
vasodilation.  
↑ mucous secretion.

• sympathetic → bronchodilation.  
↓ mucous secretion.  
vasoconstriction.

## Applied

① Bronchial Asthma. → due to bronchoospasm.  
• inspiration ✓ normal  
• expiration difficult  
+ Excessive mucous. → but no effective cough

↓↓↓  
difficult breathing → wheezing

② Aspiration pneumonia → ~~aspiration~~ →

③ Bronchiectasis → permanent dilation of bronchi & tubes  
→ pw filled → airway obstruction

## Bronchopulmonary Segments

- smallest, independent, well defined - anatomical, functional & surgical units of lungs.
- they are circled by segmental bronchi.

### Features

- pyramidal shape with apex towards hilum.
- circled by segmental bronchi
- each segment has its own artery → segmental branch of pulmonary artery.

drained by  
Intersegmental  
veins.

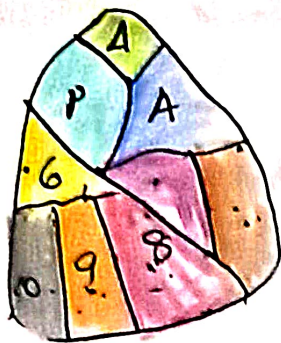
↳ its own lymphatic drainage.

↳ Autonomic Nerve supply.

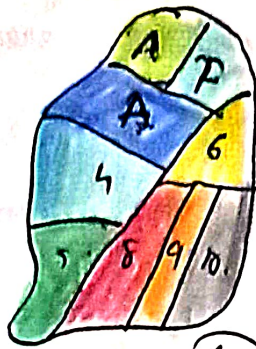
- Surgically resectable.



Lateral view.

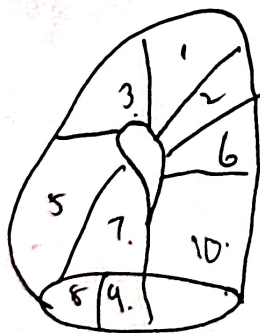


(No 7A)

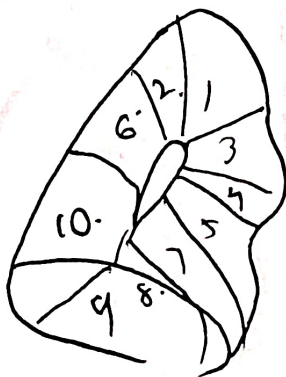


(No-7A)

medial view



not 4 seen x



(all seen)