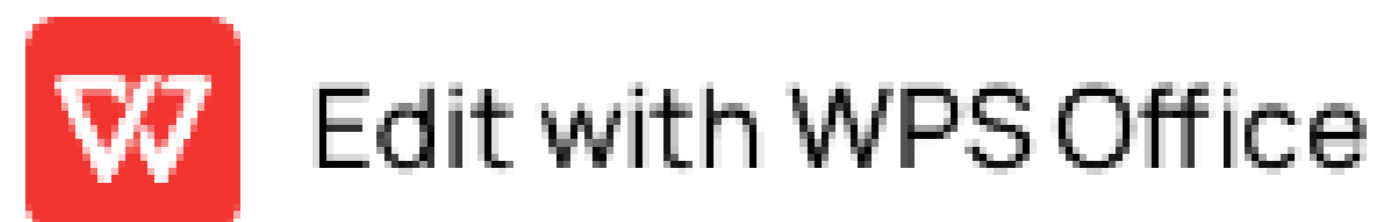



OSPE GENETICS (5 marks)



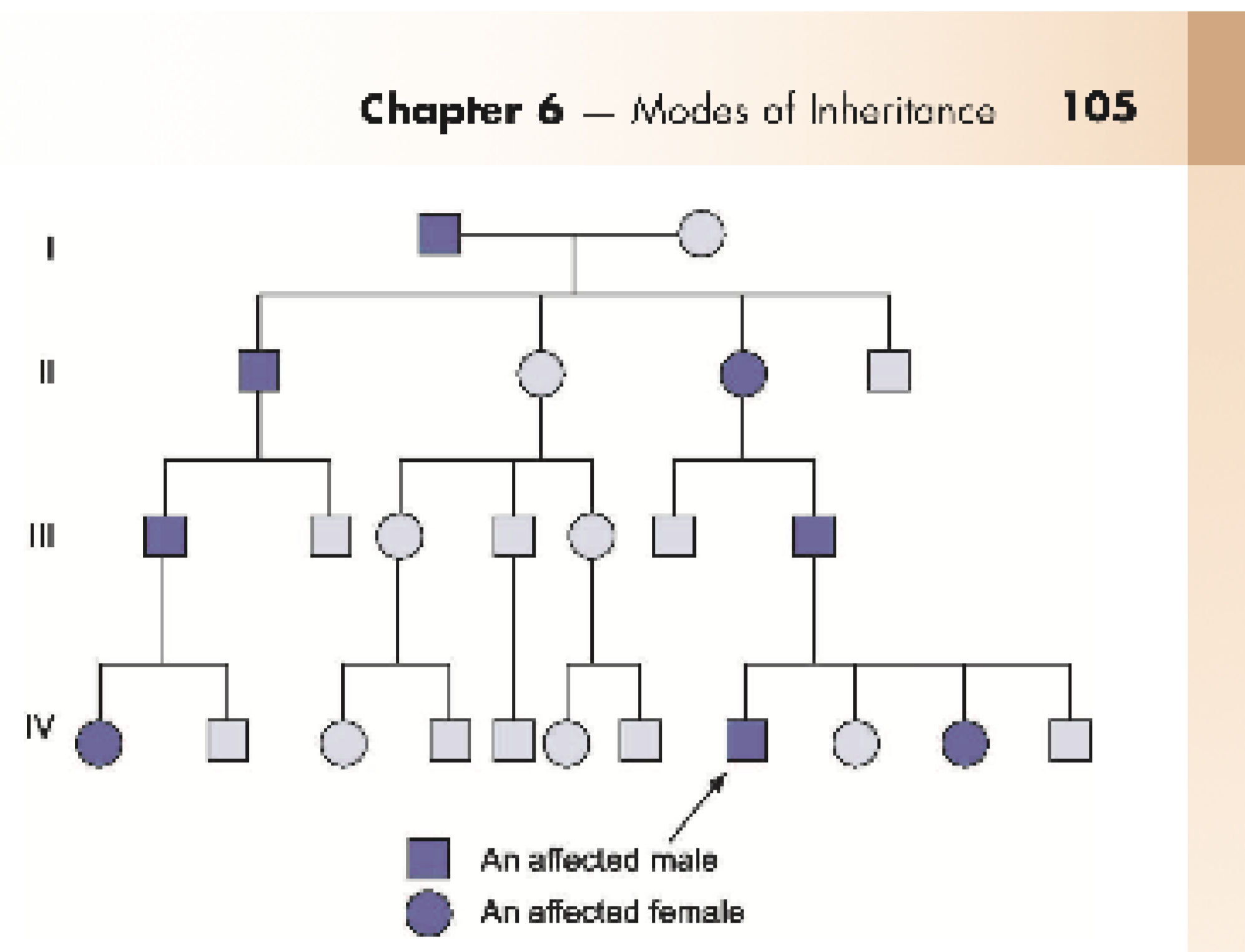
Tips to identify our ospe charts

- If the Pedigree shows a carrier, then it is always recessive. (either x-linked or autosomal recessive)
- So the carrier with a  is x-linked recessive, and a carrier with  is autosomal recessive
- If the Pedigree don't contain any carrier, then it is dominant trait
- The one with four generation is autosomal dominant and other with three generation is x-linked



Edit with WPS Office

Autosomal dominant



Pedigree analysis

In case of an autosomal dominant trait, pedigree shows the following criteria (Fig. 6.1):

1. An affected person has an affected parent, exception being mutant gene.
2. An affected person has normal and abnormal offsprings in equal proportion, i.e. there is 50% chance of dominant trait being transmitted to offsprings from affected parent.
3. Both males and females are equally affected.
4. The trait appears in every generation without skipping. An exception to this could be the trait impairing reproductive capacity of an affected person.
5. Normal children of an affected person do not transmit the disease.

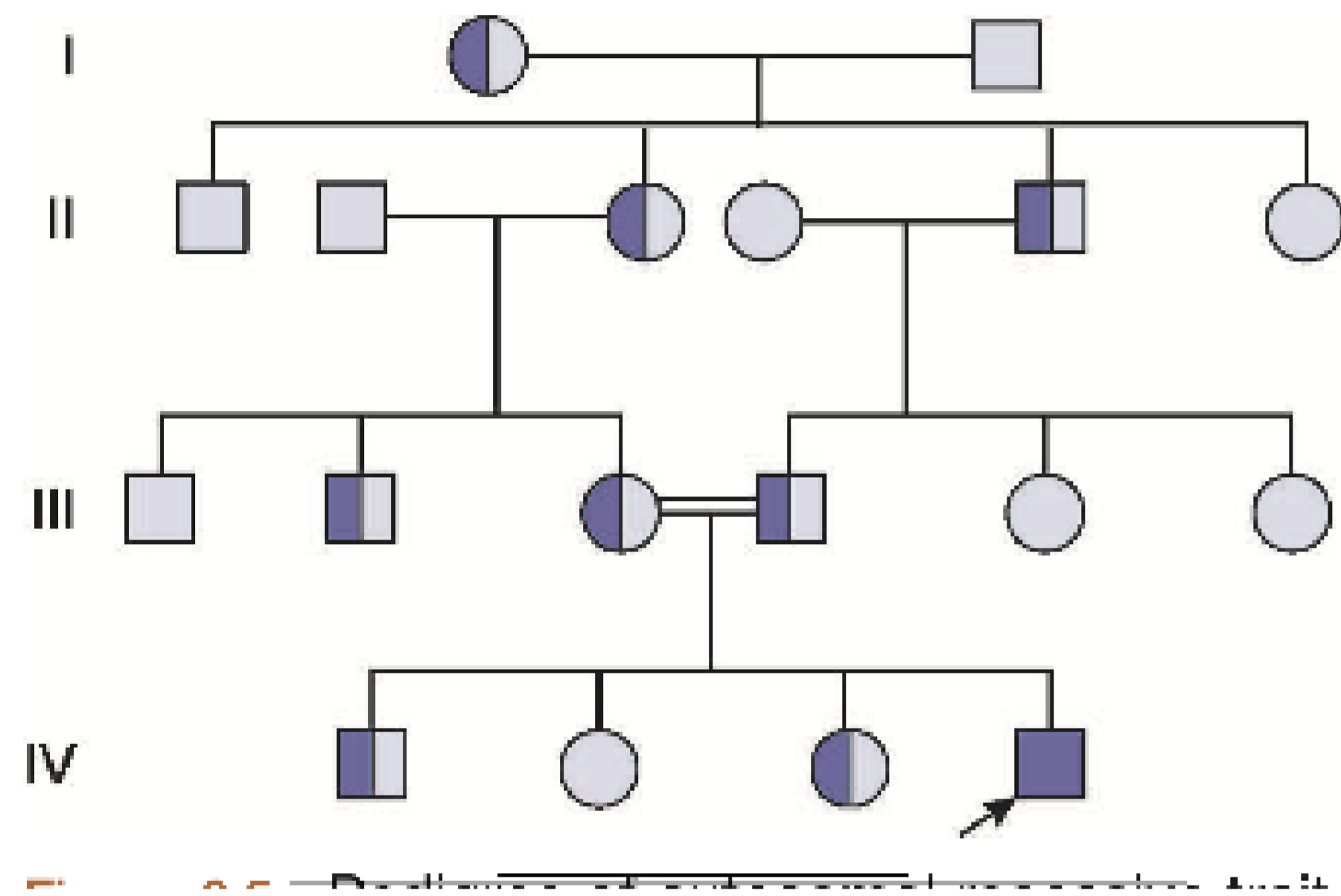
1. Identify-autosomal dominant
2. Two points to substantiate-write any two given above
3. To clinical condition-Marfan's syndrome, achondroplasia, Huntington's disease ,Treacher Collins syndrome



Edit with WPS Office

Autosomal recessive

clinical manifestation of the disease. In genetics,



Features for autosomal recessive trait (Fig. 6.5)

These are as follows:

1. The trait appears in sibs and not in parents or offsprings.
2. About 25% of the sibs of the proband are affected, i.e. the risk is 1 in 4.
3. Both males and females have an equal chance of getting affected.
4. Parents of proband may be consanguineous.

1. Identify-autosomal recessive
2. Three features-given above
3. Clinical condition-CysticFibrosis, sicklecell anaemia,

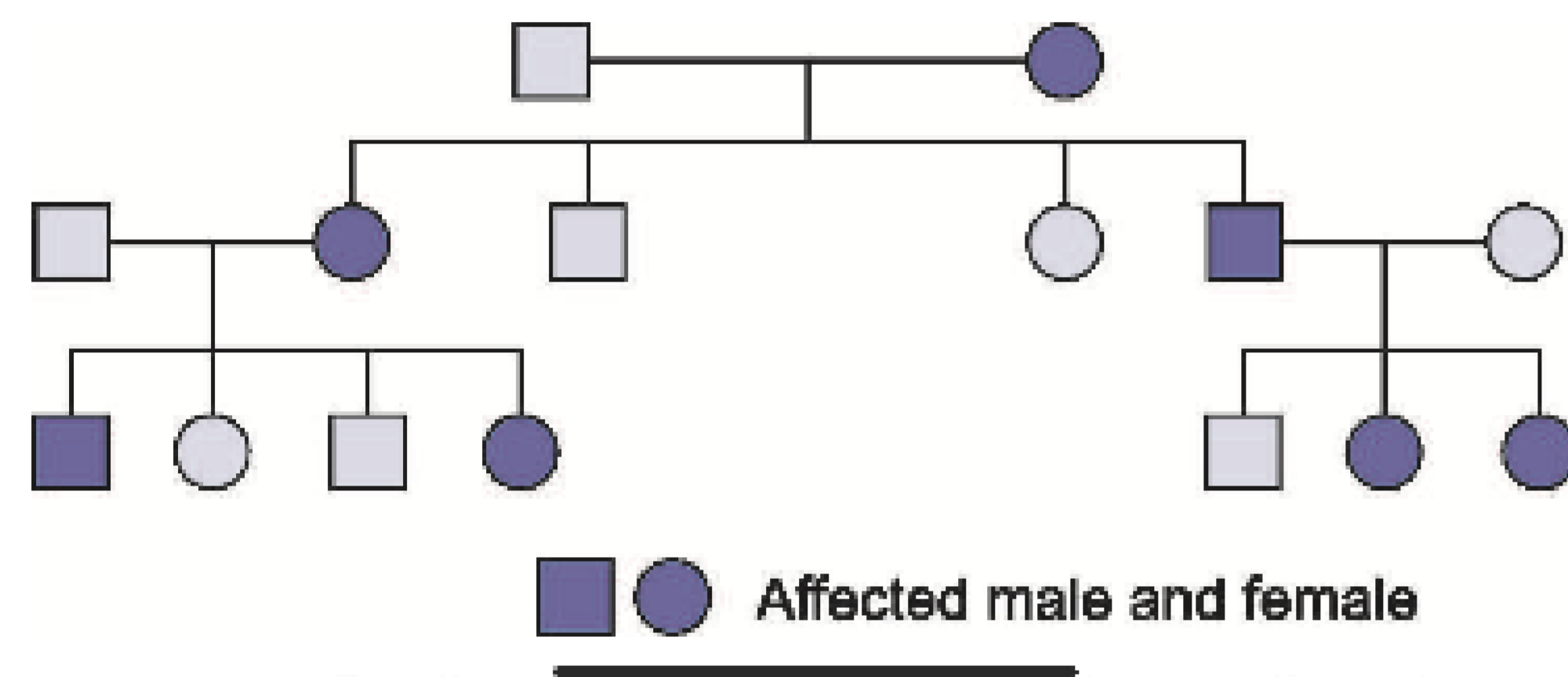


Edit with WPS Office

X-linked dominant

tics called "Fragile X syndrome". It is unique in the sense that caused by a combination of a mutant gene with an associated genetic abnormality. It is clear that the mutant gene is X-linked, it is difficult to say whether it is dominant or recessive.

clinical presentation of a fragile X case includes large prominent large sized testes after puberty along with mental retardation. ct, fragile X syndrome forms one of the important causes of



Features of X-linked dominant inheritance (Fig. 6.11)

1. Trait is more frequent in females than in males who present relatively milder expression of the disorder.
2. Affected male transmits the trait to all his daughters and not to his sons.
3. Affected homozygote female transmits trait to all children.
4. An affected heterozygote female transmits the trait to half her children of either sex. This mimics autosomal dominant transmission; hence, to distinguish between autosomal and X-linked dominant inheritance, one has to follow progeny of affected male.

1. Identify-X-linked dominant
2. Three features-given above
3. Clinical condition- vitamin D resistant ricket, fragile X syndrome, Rett syndrome



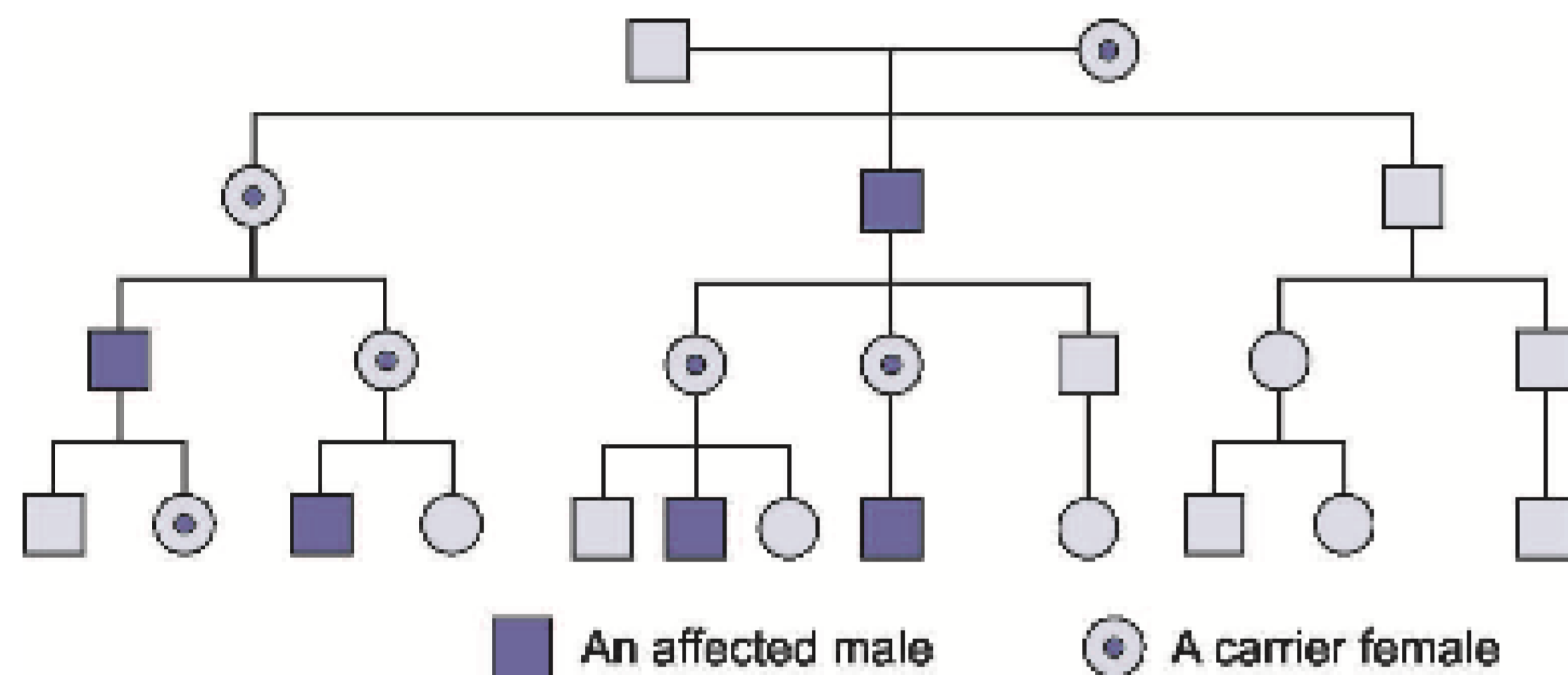
Edit with WPS Office

X-linked recessive

(X _h Y)		...	
Y	X _h Y	X _h Y	

All sons are normal and all daughters are carriers

Figure 6.9 Checkerboard showing offsprings of an affected male and normal female in haemophilia.



Features of X-linked recessive inheritance (Fig. 6.10)

Features of X-linked inheritance are as follows:

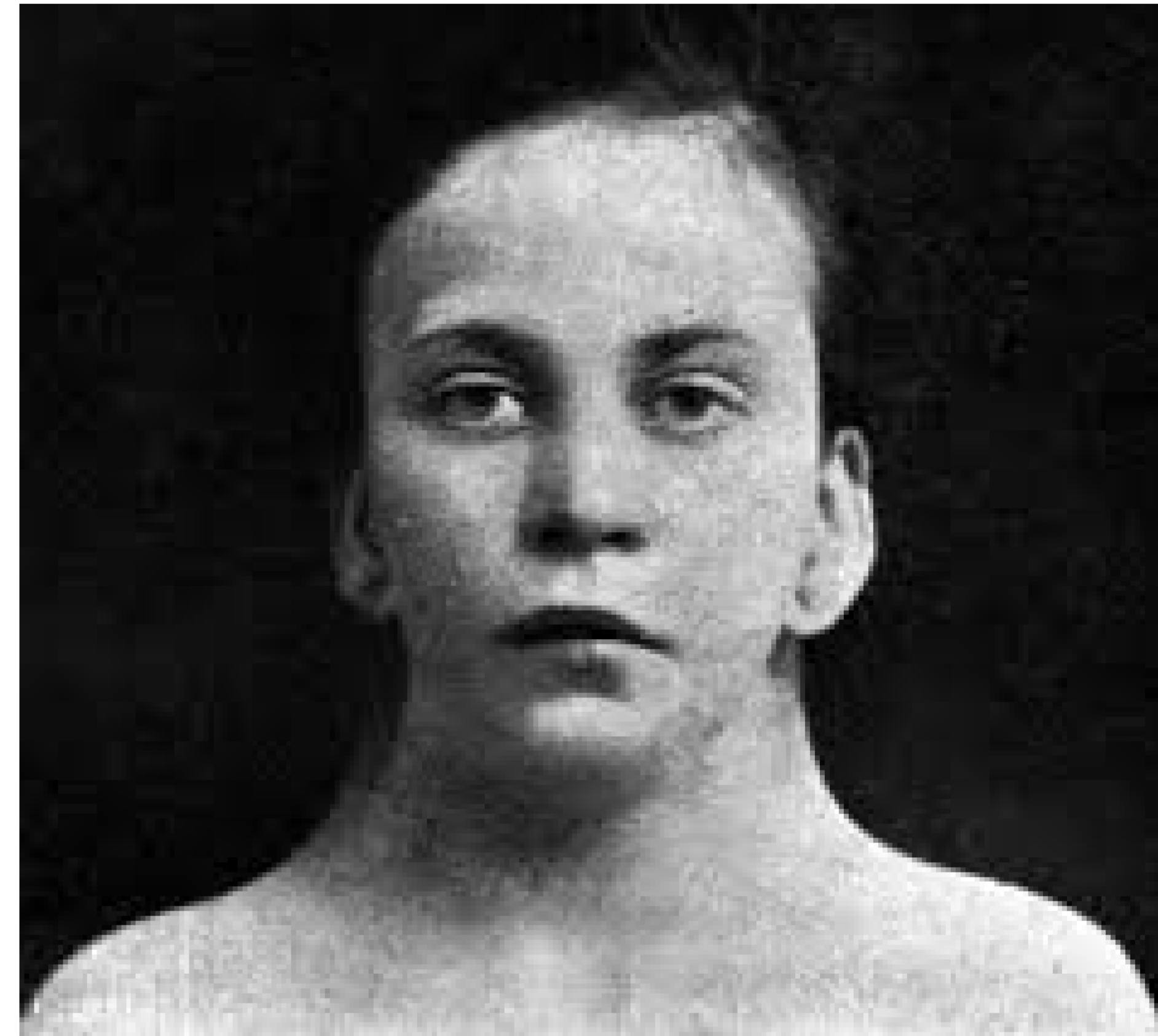1. The trait affects males (rarely females).
2. The trait is transmitted from an affected male through all his daughters to half of their sons.
3. No male to male transmission occurs, since father contributes only Y chromosome to his sons.
4. In a kindred, affected males are related to each other through carrier females.

1. Identify-X linked recessive
2. Features-given above
3. Clinical condition-haemophilia, Duchenne muscular dystrophy G6PD deficiency, colour blindness



Edit with WPS Office

Turner syndrome



1. Identify-turners syndrome
2. Clinical features-Webbed neck, short stature, streak ovary, sterility, a shield chest, under developed breast,coarctation of aorta, cubitus valgus
3. Karyotype-45 X0

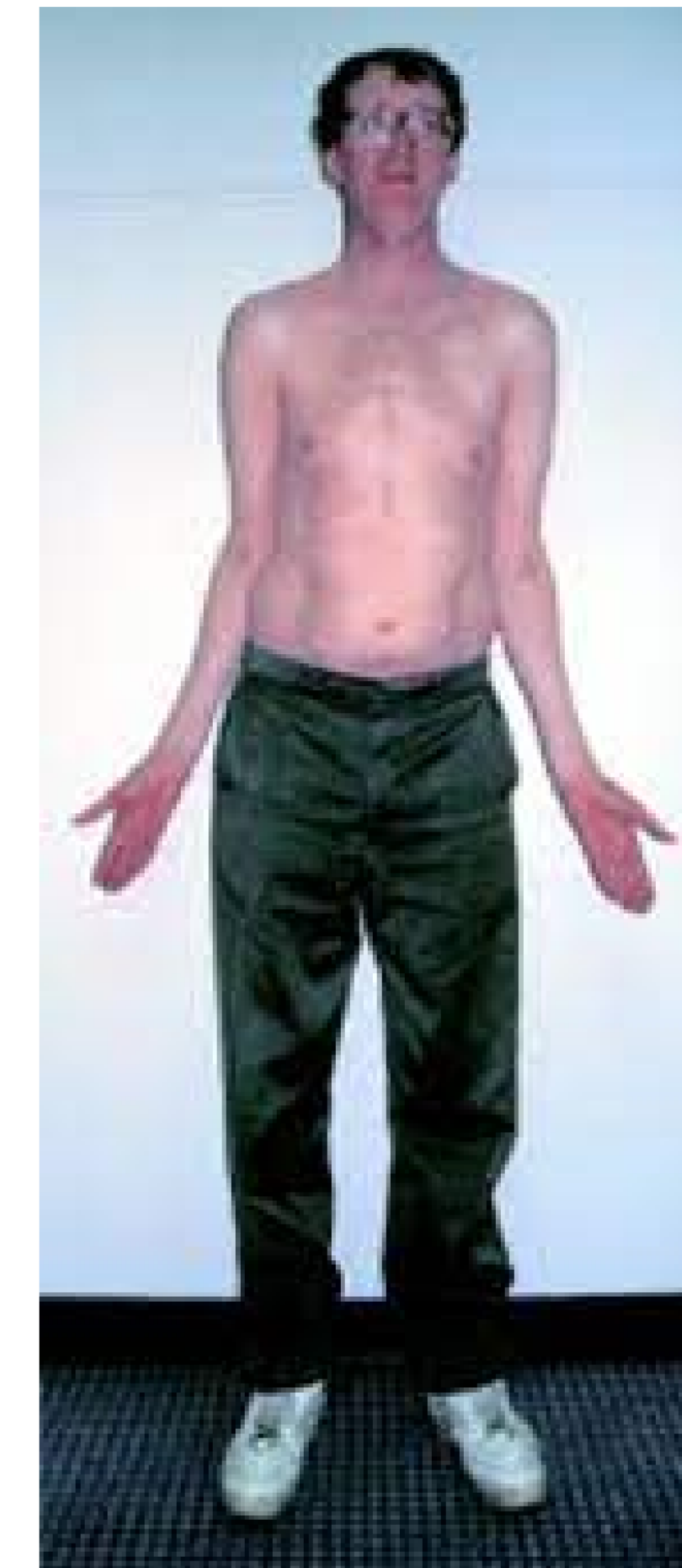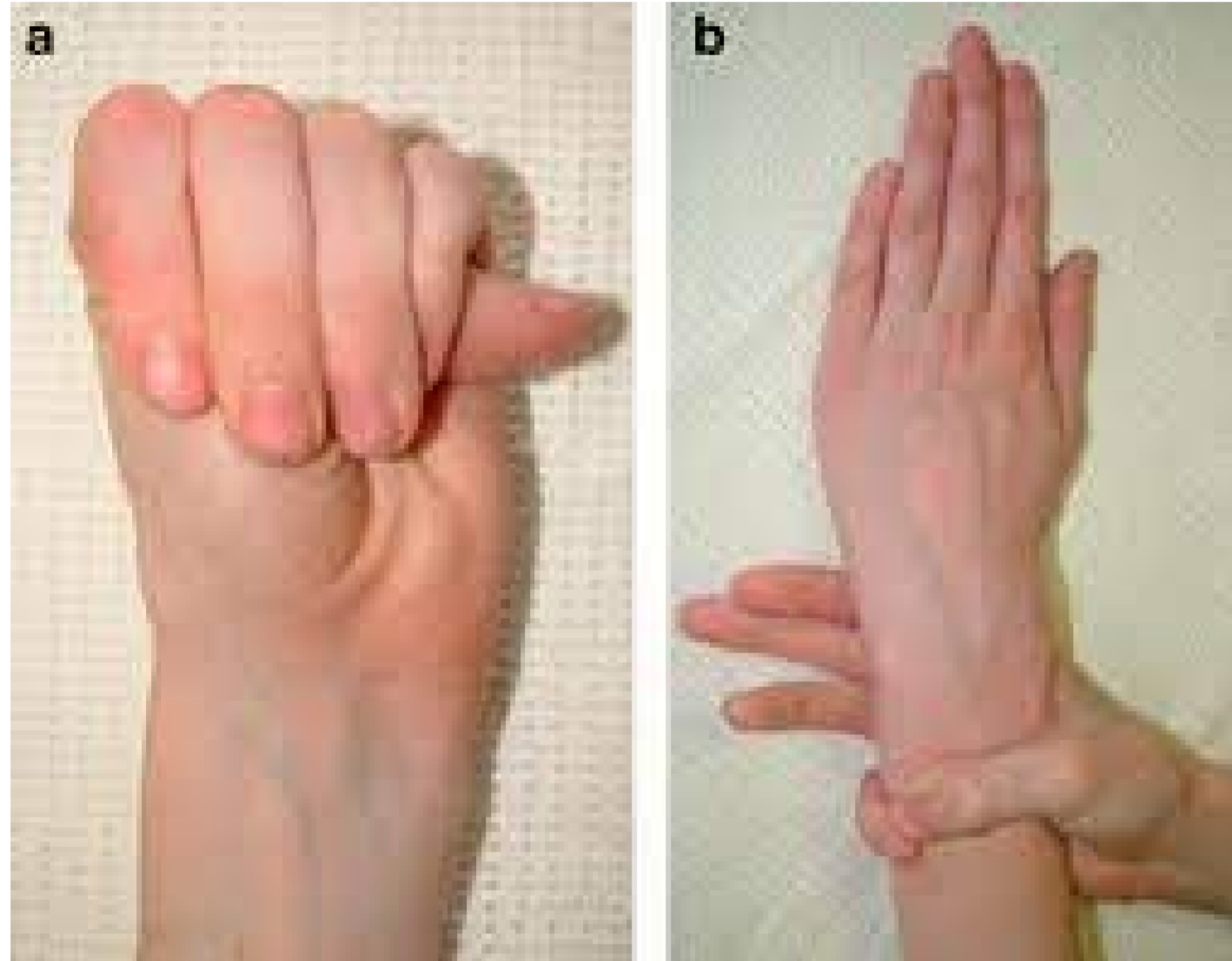Achondroplasia

1. Identify-achondroplasia
2. Mendelian inheritance associated-autosomal dominant
3. Features-shorts stature, normal intelligence, short and thick fingers, enlarged head with prominent forehead, scooped out nasal bridge, prominent facies, disproportionately shortened long bones



Edit with WPS Office

Marfan's syndrome



1. Condition Marfan's syndrome
2. Mendelian inheritance-autosomal dominant
3. Features-arm span > body height, archnodactyly, pectus excavatum, kyphosis, dilation of aorta-Aortic regurgitation, subluxation of lens



Edit with WPS Office

Down syndrome

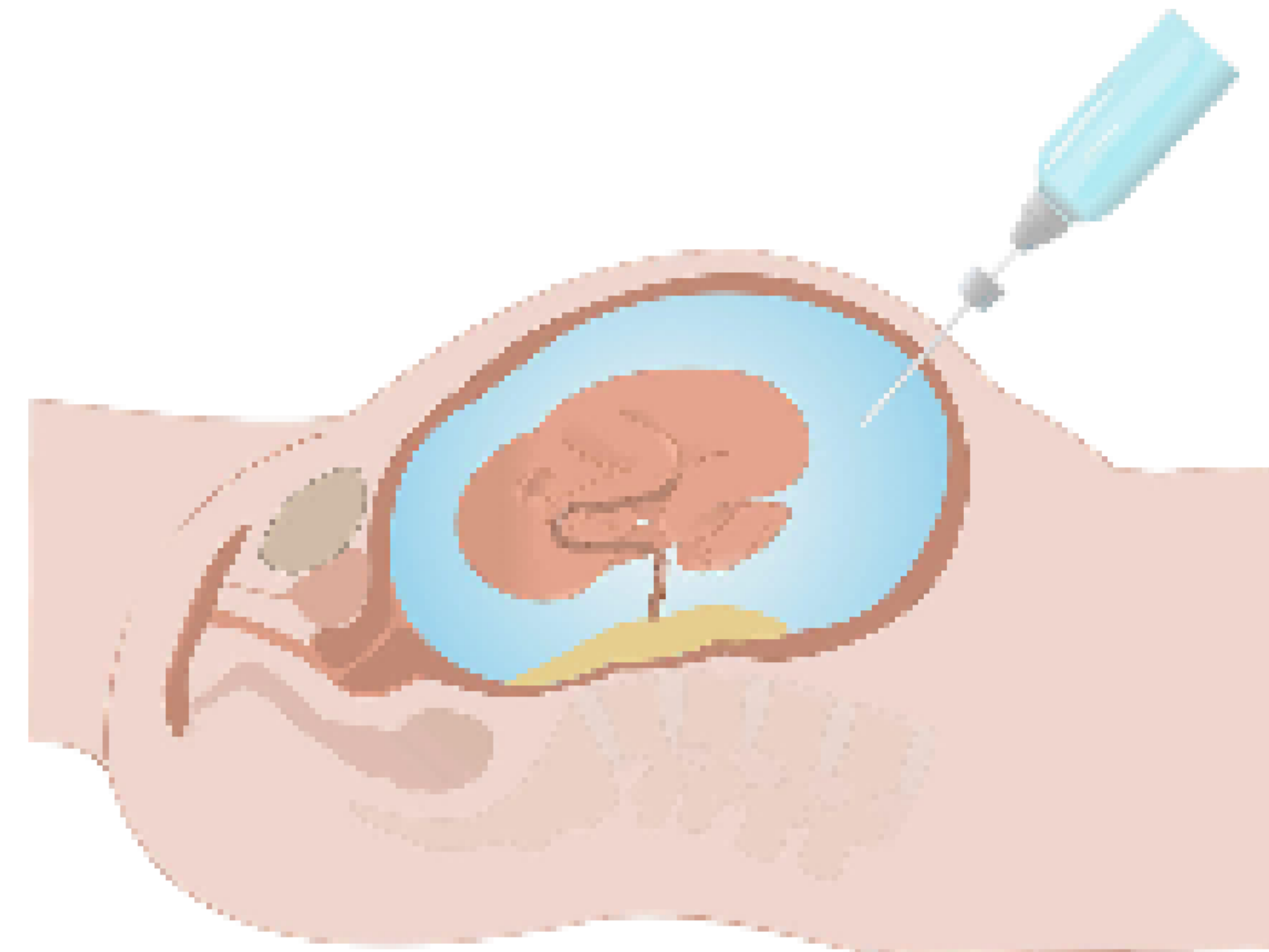


1. Condition down syndrome
2. Features-microcephaly, protruding tongue, delayed milestones, depressed nasal bridge, Simian crease, Mongoloid slant, epicanthal fold, low set ears
3. Karyotype- trisomy of 21



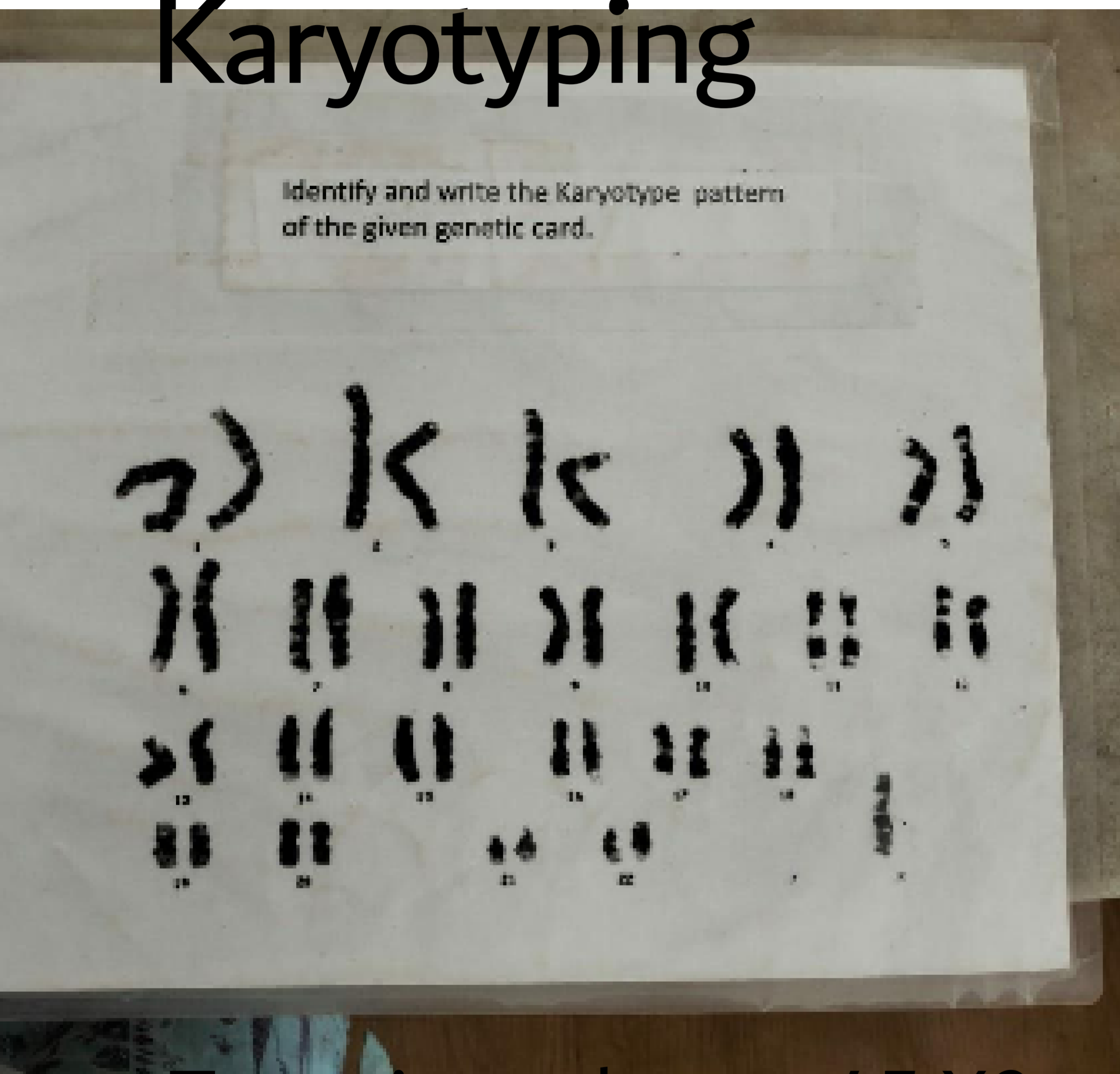
Edit with WPS Office

Amniocentesis

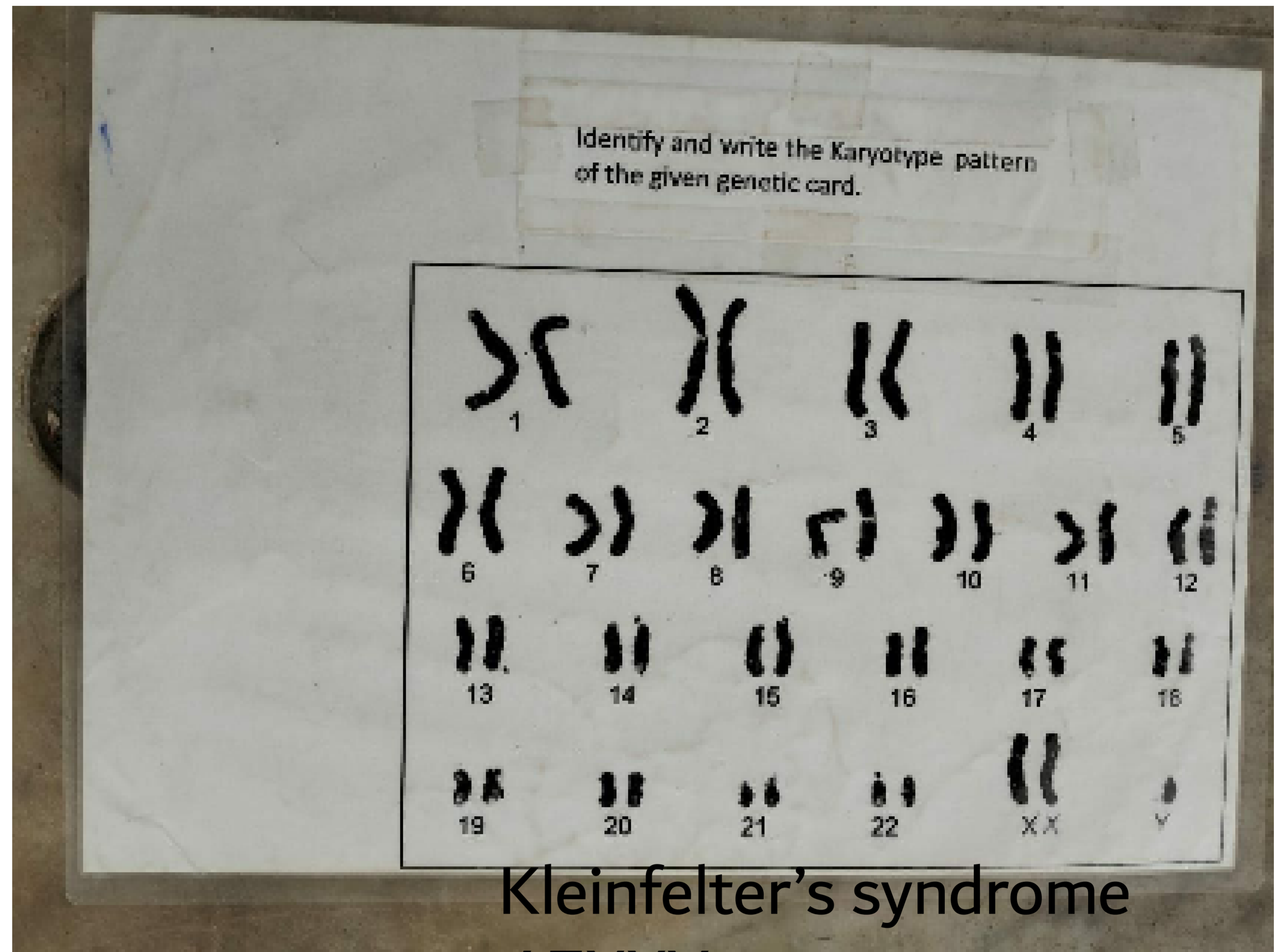


1. Procedure-amniocentesis
2. Describe the procedure: at 12 to 16 weeks: confirm position of baby by auscultation. Aspirate the amniotic fluid. The needle is inserted through the flank of the mother. Taking care not to injure the foetus/umbilical cord, maybe USG guided. Fluid send for analysis-chromosomal and biochemical studies.
3. Indications-recurrent abortions, family history of genetic anomalies

Karyotyping



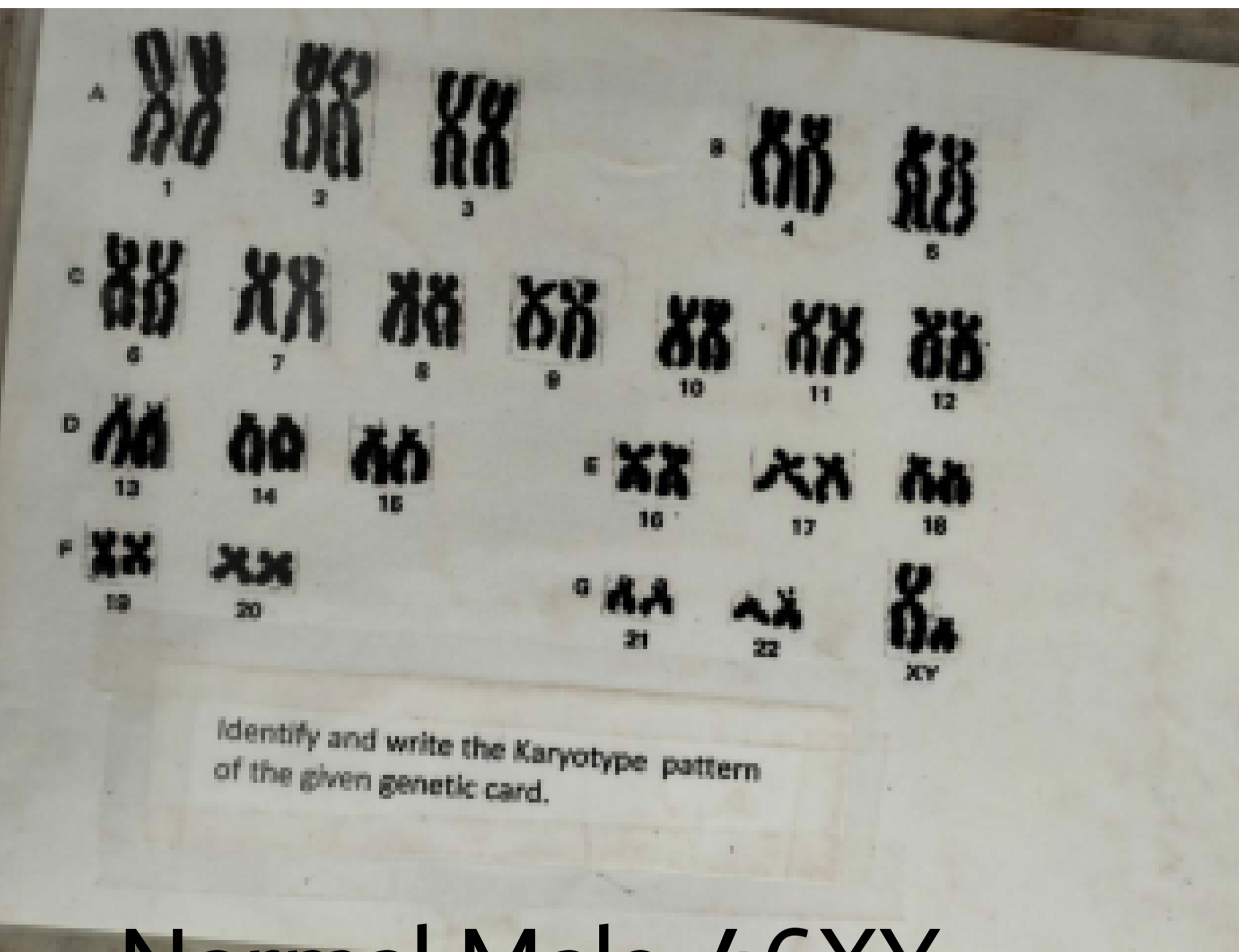
Turner's syndrome -45 X0



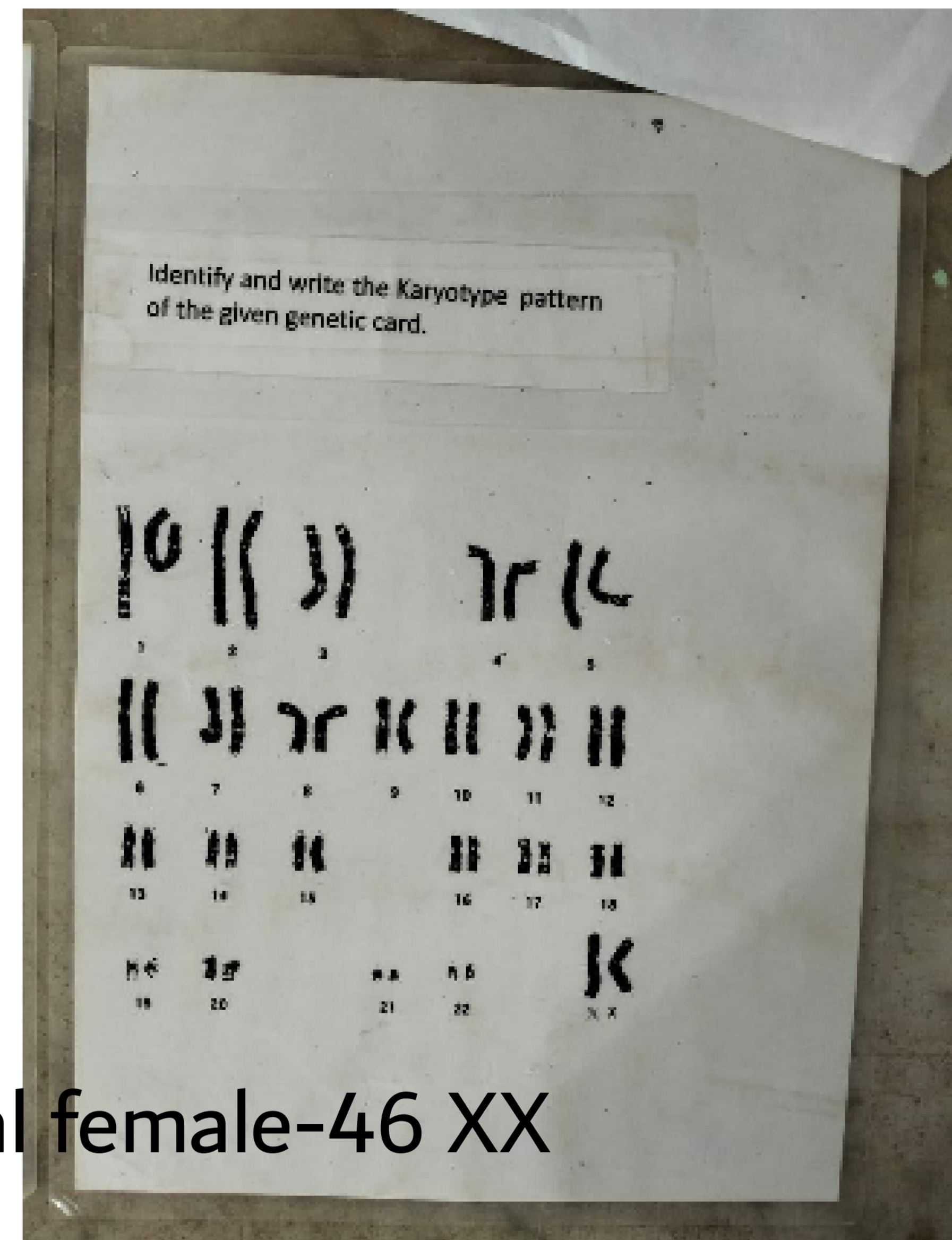
Klinefelter's syndrome
-47XXY



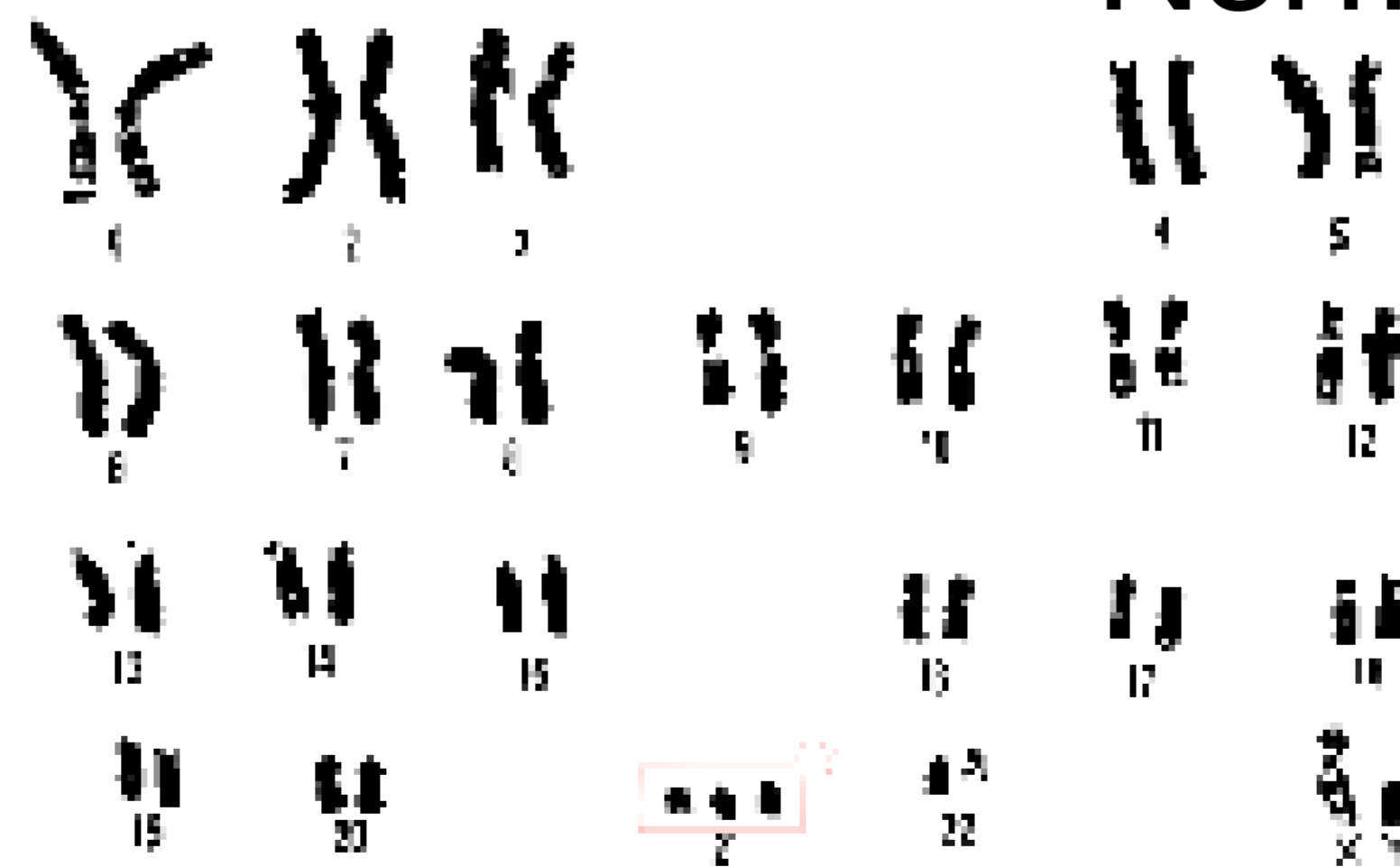
Edit with WPS Office



Normal Male-46XY.



Normal female-46 XX



Trisomy 21-47 XX + 21