

Tibial Nerve (L₄ L₅ S₁ S₂ S₃)

- Largest terminal branch of sciatic nerve.

Origin

- terminal branch of sciatic nerve at ^{joint of} middle 1/3rd & lower 1/3rd of thigh.

Course

- runs through popliteal fossa - superficial to pop. nerve & vein.

- runs through posterior compartment of leg

- enters sole of foot. → ^{passing} under flexor retinaculum of foot.

- divide to medial & lateral plantar nerves

DISTRIBUTION

Motors

→ in popliteal fossa → • Medial & lateral head of gastrocnemius
• plantaris
• popliteus

→ in leg → • Soleus.
• flexor digitorum longus.
• Tibialis posterior.
• Flexor hallucis longus.

→ sole of foot

medial plantar

- Abductor hallucis.
- Flexor digitorum brevis.
- Flexor hallucis brevis.
- 1st lumbrical.

lateral plantar

- Flexor digitorum
• Abductor digiti minimi
- Flexor digiti minimi
brevis.
- 2nd, 3rd, 4th lumbrical.
- all Interossei
- Abductor hallucis.

Sensory

cutaneous → arise in popliteal fossa.

↳ leave fossa by passing roof.

① Sural nerve.

② sole of foot → skin on sole of foot +
plantar aspect of toes +

dorsal aspect of distal phalanx

Genicular

• Supply knee joint

INJURY

① wound in popliteal fossa, posterior dislocation of knee.

→ Foot is dorsiflexed & evulsed.

↓
paralysis of
flexors of
ankle.

Sensory loss

↓
sole of foot

+ toes

+ toes dorsal - distal
phalanx

② Tarsal tunnel syndrome. → compression in tarsal tunnel.
pain & paraesthesia in sole of foot.

Common Peroneal nerve. (L4 L5 S1 S2) ~~S2~~

Smaller terminal branch of sciatic nerve.

⇒ ~~emerge~~ emerge at joint of middle 1/3 & lower 1/3 of Thigh.

⇒ runs along → lateral border of popliteal fossa.

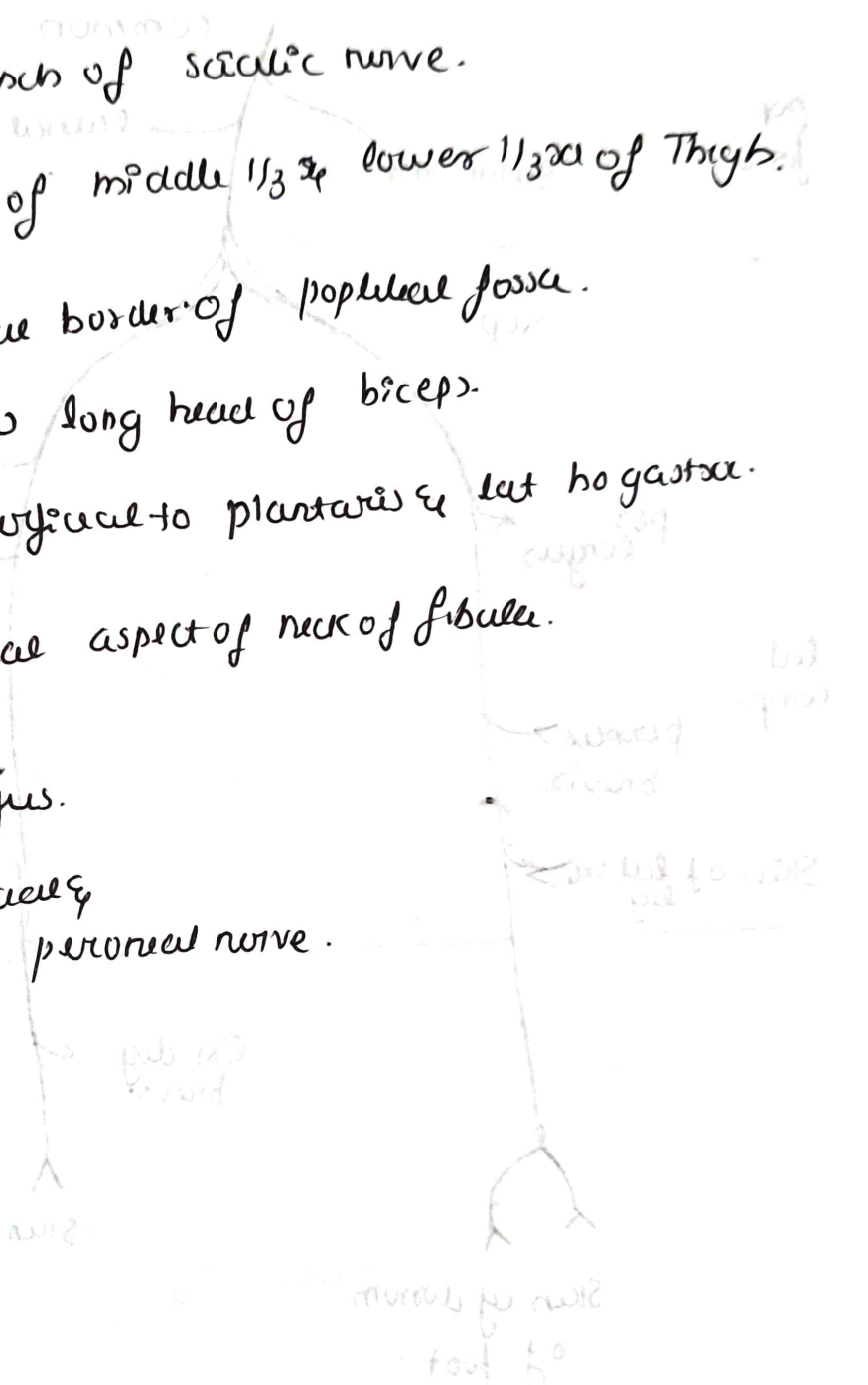
→ below long head of biceps.

→ superficial to plantaris & lat. gastrocnemius.

⇒ winds around lateral aspect of neck of fibula.

⇒ pierces peroneus longus.

⇒ terminal → superficial & deep peroneal nerve.



branches

Common peroneal

Radial sural nerve.

Sural comm.

pop fossa.

Sup

deep.

libialis anterior.

Extensor hallucis longus

per longus.

Ant
Extensor digitorum longus

left comp.

peroneus brevis.

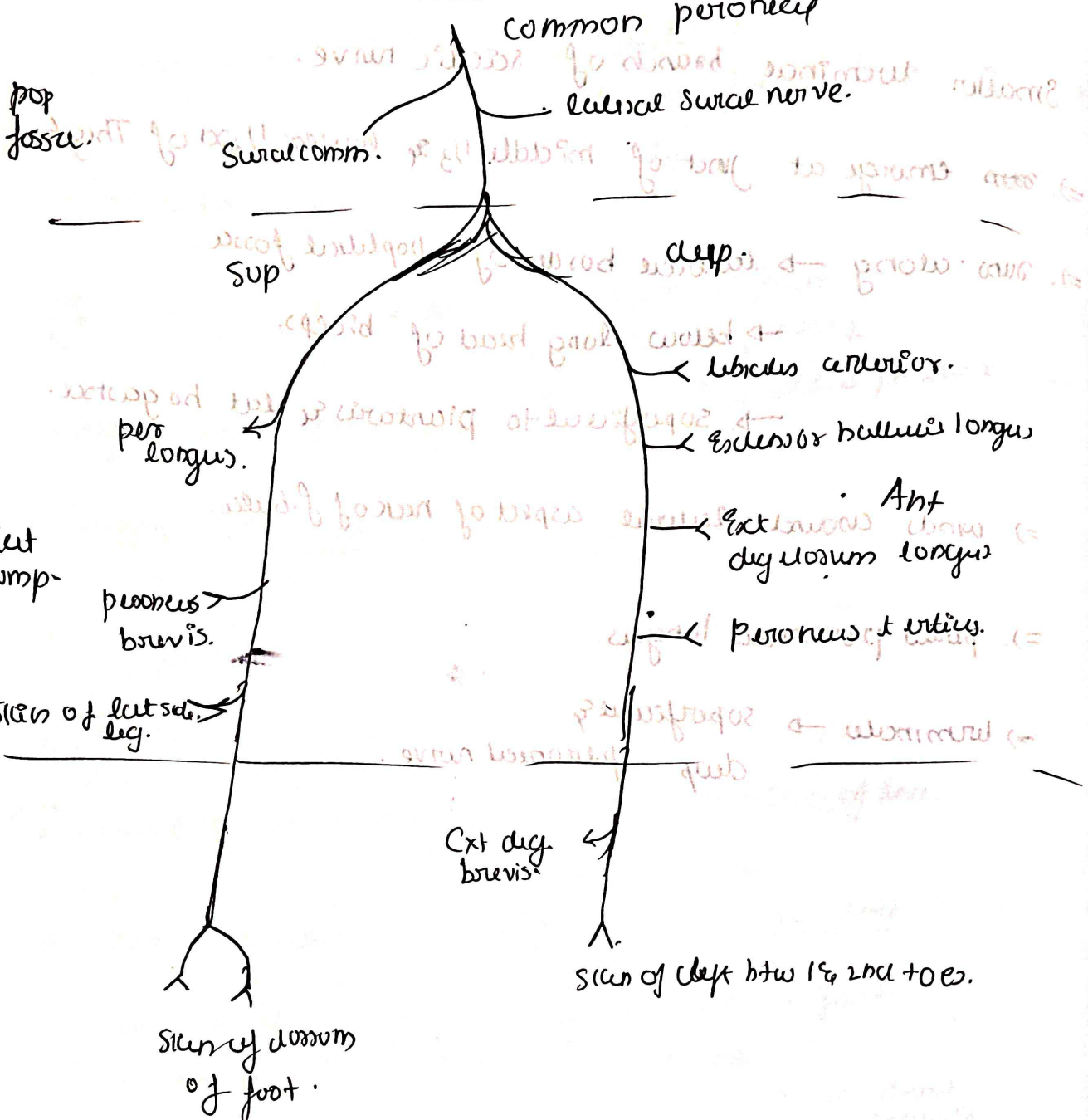
Peroneus tertius.

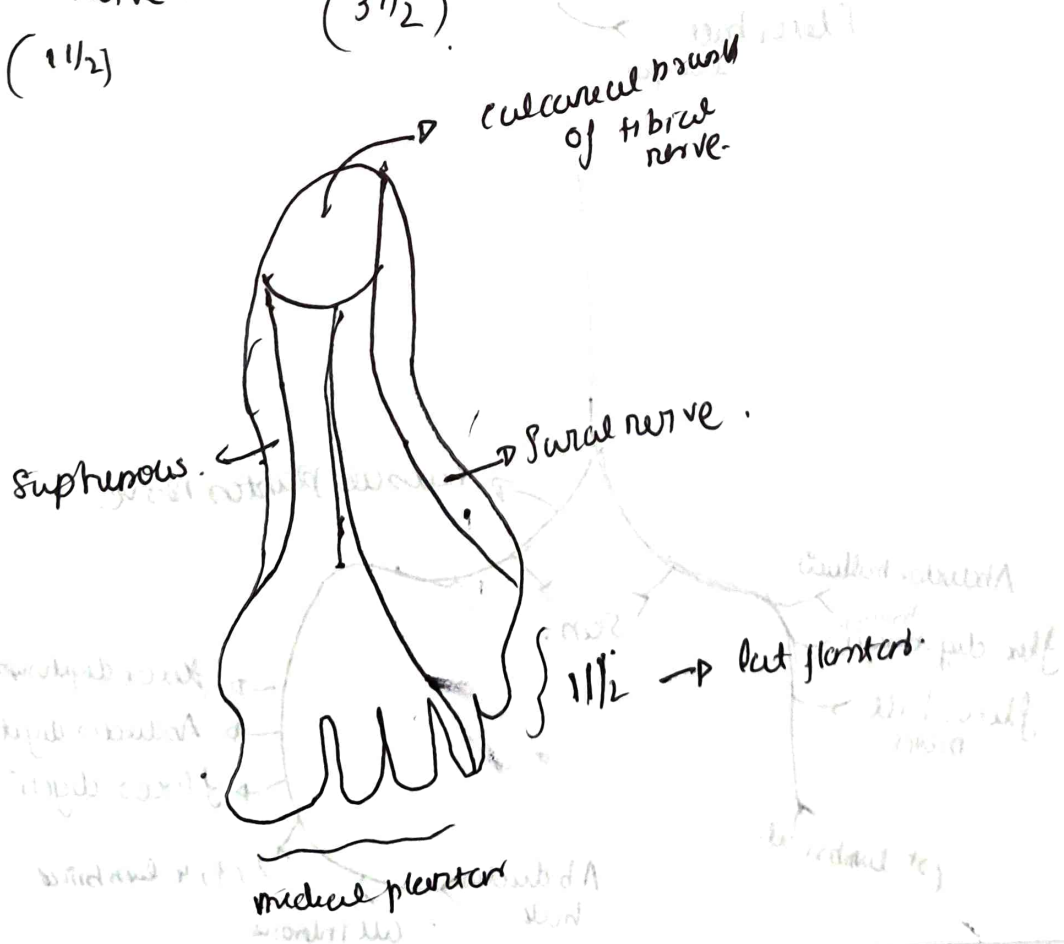
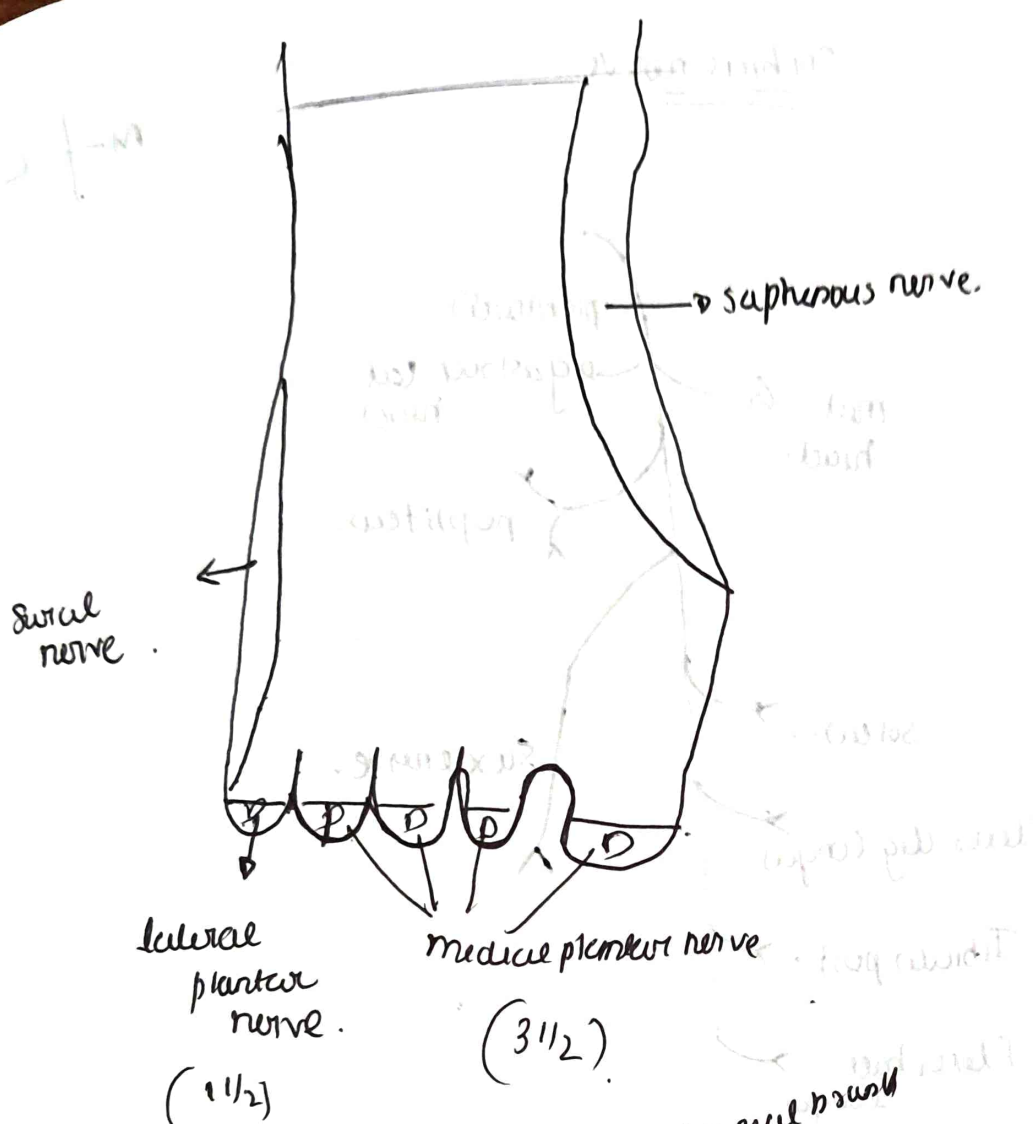
Stem of left side leg.

Ext dig brevis

Stem of left btw 1st & 2nd toes.

Stem of dorsum of foot.





Tibial nerve

m + 2

