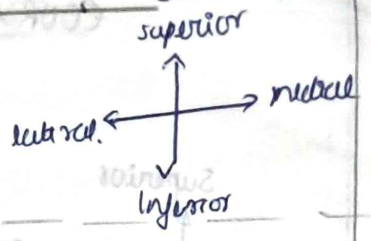
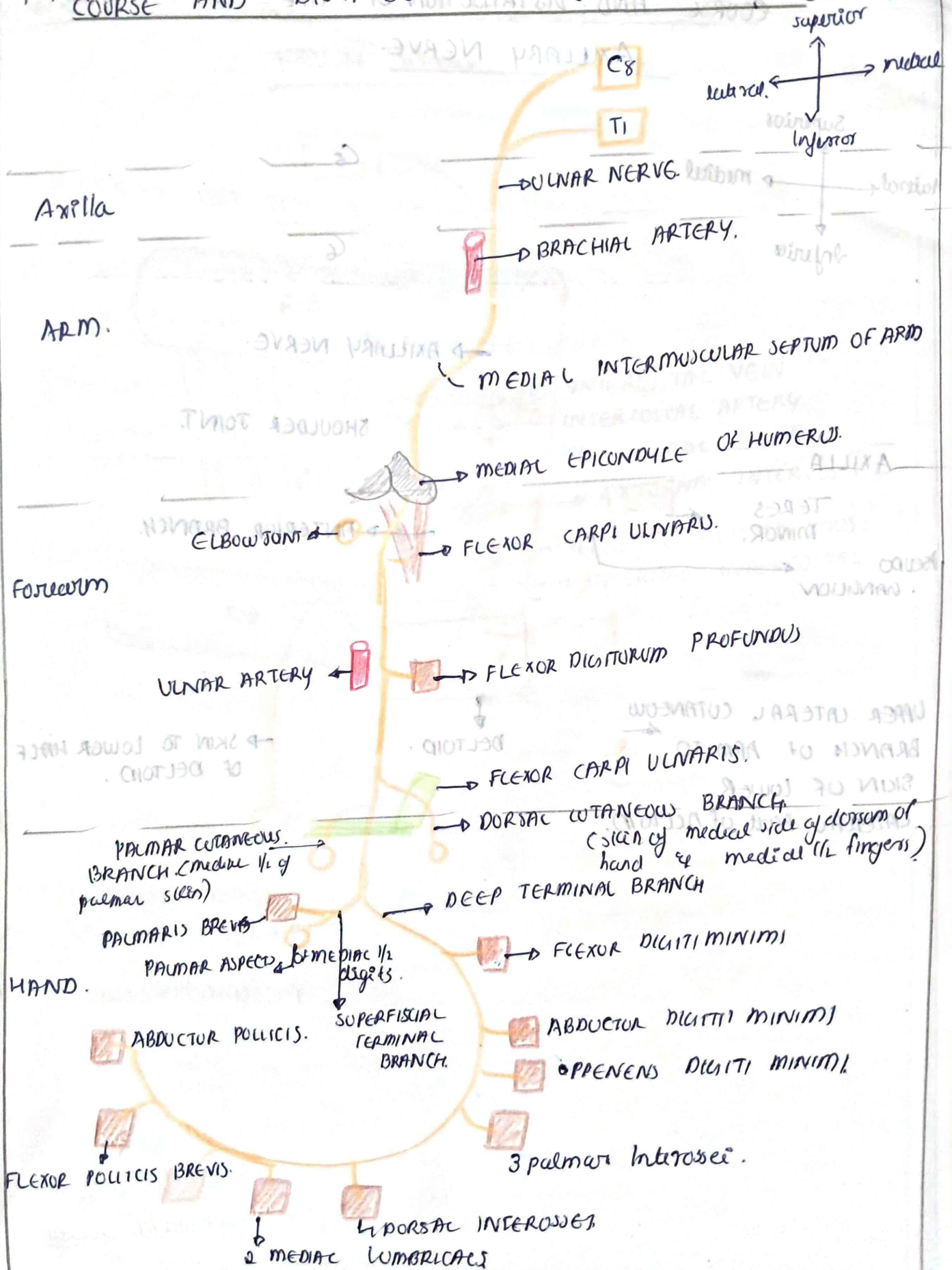


26/10/23

COURSE AND DISTRIBUTION OF THE ULNAR NERVE.



axilla → medial to 2nd & 3rd part of axillary artery.

arm → medial to brachial artery.

middle of arm.

passes → medial intermuscular septum.

↓
enters posterior compartment of arm.

↓
behind medial epicondyle of humerus.

↓
between 2 heads of flexor carpi ulnaris

↓
in forearm.

forearm branches

supplies flexor carpi ulnaris.

flexor digitorum profundus (medial half).

palmar ulnar nerve. → medial 2 1/2 palmar.

dorsal ulnar nerve. → 2 1/2 dorsal. medial

↓
hand


front of flexor retinaculum.

↓
superficial & deep branches.

→ Volcar tunnel.

→ funny bone

→ claw hand

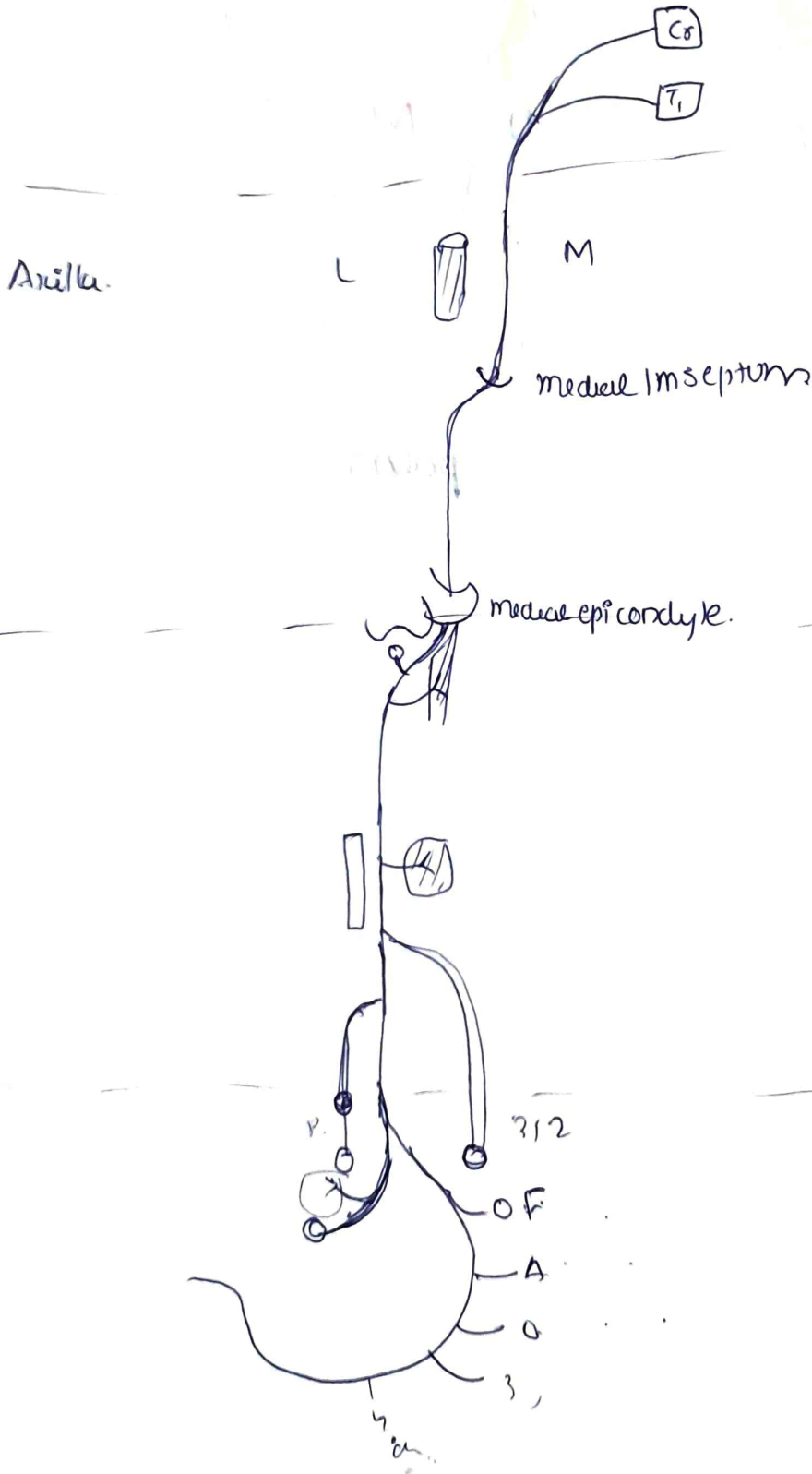


A part of right hand
near front of arm

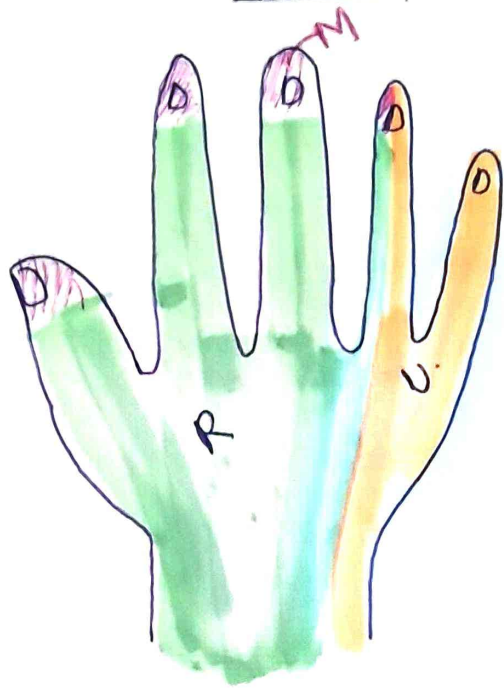
Ulnar nerve (C8 T1)

⇒ arises from ~~posterior~~ ^{medial} cord of brachial plexus.

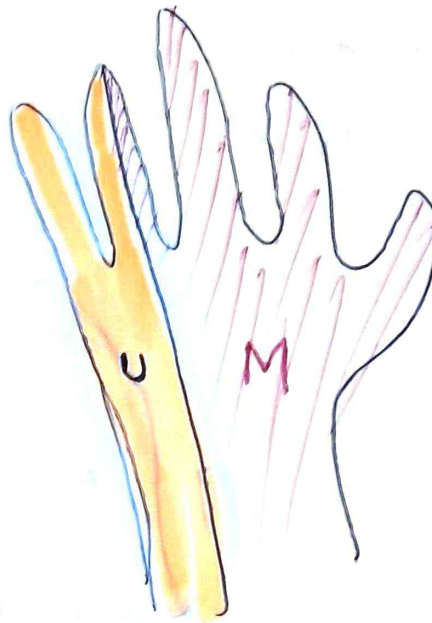
⇒ Muscularis nerve.



Cutaneous Innervation of Hand



dorsum



palmar