

Fascial Spaces of Hand.

- > due to arrangement of various fascia & fascial septa.
- > potential spaces, -> becomes obvious when -> pus collection

A. Palmar Spaces

Midpalmar space.

Thenar space.

Pulp space of digits.

B. Dorsal spaces

Dorsal Subcutaneous space.

Dorsal Subaponeurotic space.

C. Space of Parona.

Midpalmar Space *

• Δ space.

Boundaries

anteriorly: superficial to deep.

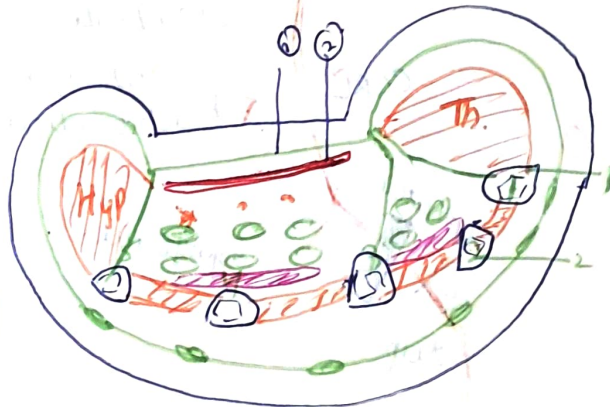
- ① palmar aponeurosis.
- ② superficial palmar arch.
- ③ digital nerves & vessels
 { medical 3 1/2 fingers }
 supply
- ④ ulnar bursa enclosing
 flexor tendons of medial 2
 fingers.
- ⑤ 2nd, 3rd & 4th Lumbricals.

posteriorly -> medial 3 metacarpals &

Interossei.

lateral: -> Intermediate palmar septum, -> ^{lateral.} ~~radial~~ edge of palmar apo.

medial -> medial palmar septum { wide extent }
 to 3rd metacarpal.



• proximal -> forearm part of Parona.

• distal -> medial 3 web space

Thenar space

Anterior → Palmar aponeurosis
digital nerves & vessels of lateral 1 1/2 digits.
flexor tendon of FPL
flexor tendon of index finger.
first lumbrical.

posterior → adductor pollicis.

medial → Intermediate palmar
septum.

lateral → lateral palmar
septum [Eckert].

Distal. → first web space through
first lumbrical canal.

Injection of midpalmar space → incision of medial 2 web space.

do " " Thenar space → first web space incision.

Pulp Spaces of Digits - Whitlow, Julon.

→ Subcutaneous spaces on palmar side of fingers & lips

Superficially → skin
superficial fascia

deeply → distal 2/3rd of distal phalanx.

Features: space is ~~formed~~ contains septa from skin to periosteum of distal
phalanx.
forms many locules.

digital artery supplying diaphysis of phalanx runs through this space.

epiphysis of distal phalanx receives blood supply proximal to pulp space.

pulp space abscess \rightarrow felon \rightarrow severe throbbing pain.

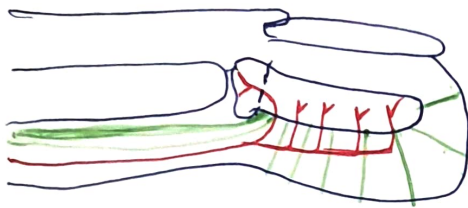
\downarrow
pw is drained by lateral incision opening all loculi

\downarrow
avoiding tactile skin sensation on front of finger.

\downarrow
if neglected can lead to avascular necrosis.

\downarrow
proximal 1/5th (epiphysis) is spared

\downarrow
as branch of digital artery supplying it does not enter pulp space.



Simple 😊

Space of Parona - forearm space.

\rightarrow Anteriorly \rightarrow tendon of FDS & FDP within ulnar bursa

tendon of FPL within radial bursa.

Proximal \rightarrow intermuscular spaces of forearm

Distal \rightarrow up to wrist.

lateral \rightarrow outer border of forearm.

medial \rightarrow inner border of forearm.

Invasions *

- **Thenar space** → vertical → first web space.
- **Midpalmar space** → vertical → medial 2 web spaces
- **Ulnar bursa** → lateral margin of hypothenar eminence
- **Radial bursa** → medial margin of thenar eminence.
- **pulp space** → vertical → side
- **paronychia** → distal part of forearm.



Dorsal spaces

- ① **Dorsal Subcutaneous space** → deep to skin on dorsum of hand.
- ② **Dorsal Synovial space** → anteriorly → medial 4 metacarpals & ulnar side
aponeurotic sheet posteriorly.
proximally → base of metacarpal
distal → MP joints.

