Submandibular gland.

- a large Salivary gland situated in anterior part of digastric triangle.
- It is a mixed Salivary (both serous & mucous).
- It extends till the stylomandibular ligament posteriorly.

PARTS → divided into 2 parts by mylohyoid muscle.

- superficial part
- deep part

] continuous along the posterior part of mylohyoid muscle.

PARTS.

- Superficial part - large. → fills in anterior part of digastric Δ.

Two ends → anterior & posterior.

3 surfaces → Inferior Surface, medial Surface, lateral Surface.

MEDIAL RELATION – medial surface is divided into 3 parts.

① Anterior part → related to: mylohyoid muscle, nerve & vessels. Submental branch of facial artery.

② Intermediate / middle → hyoglossus
~~Hyoglossus~~
Lingual & hypoglossal nerve.
Submandibular ganglion.

③ Posterior part → styloglossus muscle.
Stylohyoid ligament. ✓
Glossopharyngeal N.
wall of pharynx.

DEEP PART → Lies on hyoglossus muscle.

Laterally – mylohyoid

medially – Hyoglossus & styloglossus.

ARTERIAL SUPPLY → facial artery

VENOUS → Common facial vein.

lymphatic → Submandibular lymph nodes.

FASCIA / CAPSULE.

⇒ Investing layer of deep cervical fascia.

⇒ splits at Cornu of hyoid bone. → superficial & deep layer.

- superficial layer → covers → inferior surface of gland.
- deep layer → covers medial. surface of gland.

RELATIONS

SUPERFICIAL PART

INFERIOR. RELATIONS.

Skin
Superficial fascia.
deep fascia.
Facial vein. ✓
Submandibular lymph nodes.

LATERAL RELATIONS

- Submandibular fossa
- medial pterygoid muscle. ✓
- Facial artery. ✓

Sympathetic fibres.

Figure UQ

derived from sympathetic plexus around facial artery.

Spinal nerve

↓

Superior cervical sympathetic relay ganglion

↓

post ganglionic fibres

↓

plexus around facial artery.

↓

fibres pass through Submandibular ganglion

without relay.

SENSORY – Lingual nerve.

BRANCHES → 5 – 6

enters submandibular gland

Sublingual gland.

Nerve Supply.

A. Secretomotor fibres. / parasympathetic.

Superior Salivatory nucleus.

↓

facial nerve

↓

Chorda tympani

↓

Lingual Nerve.

↓

relay in Submandibular ganglion

↓

post ganglionic fibres.

↓

Submandibular & Sublingual glands

Sympathetic supply

T1 spinal segment.

↓

Superior cervical sympathetic ganglion.

↓

post ganglionic fibres

↓

plexus around facial artery.

↓

derived from this plexus → Submandibular gland.

SENSORY SUPPLY

⇒ by lingual Nerve.

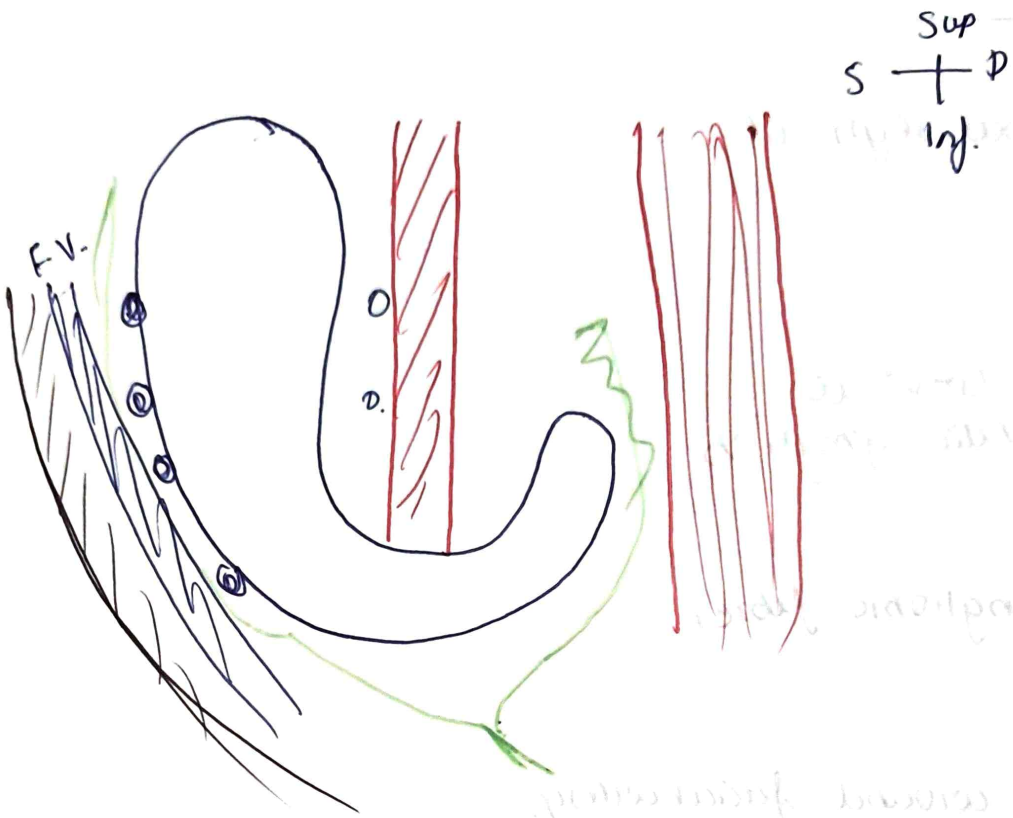

Wharton's Duct

- 5cm long.
- emerge at anterior end of deep part.
- in hyoglossus between lingual (above) & hypoglossal below.
- near anterior border of hyoglossus, it is crossed by lingual nerve.
- opens into oral cavity @ summit of sublingual papilla at side of frenulum of tongue.

Submandibular ganglion

Same - Same but different :)

- collection of cell bodies
- located in course of parasympathetic fibres supplying SM & SL salivary glands

✓ Topographically → Lingual nerve.

✓ functionally → facial nerve.

Shape → fusiform

Situation: hyoglossus muscle.

relations

superiorly → lingual nerve.

Inferiorly → deep part of submandibular gland.

✓ Connections

Parasympathetic → SS Nucleus (pre ganglionic)
↓
facial nerve.
↓
Chorda tympani
↓
Lingual nerve.
↓
relay.

post → to sub. & SL salivary glands.

Applied anatomy

- formation of calculi in Submandibular gland & duct is more common than parotid.

due to: more viscous secretion
path of duct is upwards & tortous.

- during excision → injury to marginal mandibular branch of facial nerve.
- swelling of SMG is palpated BIMANUALLY → between thumb & index.

- If swelling is below jaw in question. & said bimanually palpated to confirm] It means submandibular gland.

(UQ)

Sublingual

- duct → 20 in number.
- Bmnjo criyellenkilum
  NS same as submandibular nBmj Bordemmsmo!