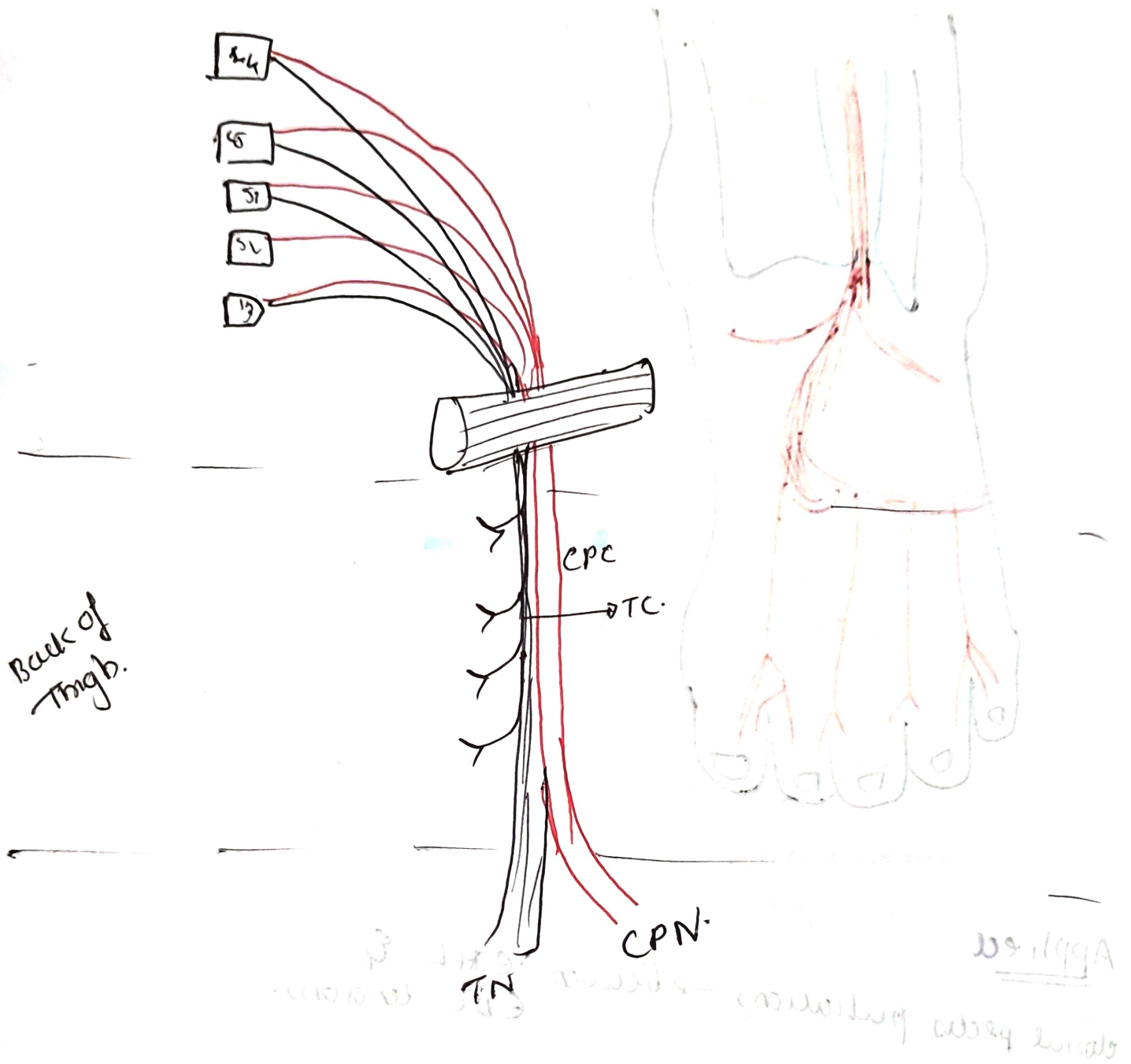


Sciatic nerve. (L4 - S3)



INTRO: Thickest nerve of body

Nerve of posterior compartment of thigh.

2 parts → Tibial & Common peroneal part

ROOT VALUE - L₄ L₅ S₁ S₂ S₃.

(ventral & dorsal divisions of ventral rami)

COURSE

• arises in pelvis.

• leaves pelvis → through greater sciatic foramen
below piriformis.

• enters gluteal region. → lies under cover of gluteus
maximus.

• passing between greater trochanter & ischial tuberosity.

• goes ^{along} ~~to~~ back of thigh. @ inferior border of GM
→ inner thigh.

• a little above popliteal fossa

@ Jnt of middle & lower 1/3 of thigh.

Terminal

↓ branches

↓
Tibial nerve and Common peroneal nerve.

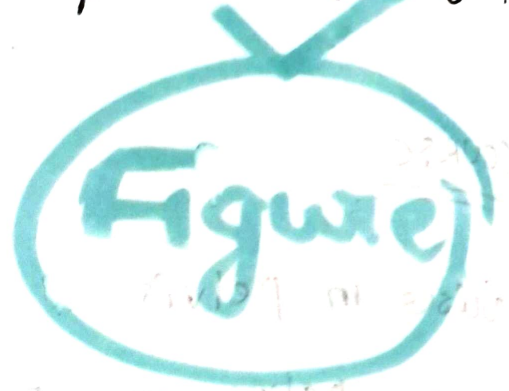
RELATIONS

Superficial → gluteus maximus. ~~posterior part of thigh~~

Deep → ✓ body of ischium.
✓ Obturator Internus
with gemelli

Nerve to Ob. Int

✓ Quadratus femoris.
✓ Adductor magnus
N to Q. femoris
hip joint



DISTRIBUTION

① Articular → to hip joint in gluteal region.

② muscular branches → to hamstring muscles - by fibular component
in posterior compartment of thigh.

from medial side of nerve.

→ semitendinosus

→ semimembranosus

→ long head of biceps f.

→ Adductor magnus (hamstring part)

✓ To short head of biceps femoris by common peroneal part

from lower part of thigh → lateral side.

Applied.

① sciatica → due to compression of nerve roots
shooting pain.

② injury → wrong intramuscular injection

in lower medial quadrant of gluteal region.

③ sleeping foot → paravertebra → due to compression.

Sciatic nerve is uncovered

between lower border of G_{max}
& long head of biceps