RPGN

definition →

pathogenesis →

classification

Type I – Anti GBM antibody	Type II : Immune complex	Type III : Pauci immune
Good pasture Syndrome.	• PSGN • Lupus nephritis • IgA nephropathy • Henoch-schonlein purpura.	ANCA associated idiopathic Wegner's Granulomatosis
Immunofluorescence m/c ↓ linear GBM fluorescence. ↓ IgG, C3 deposits.	IF: granular deposits ↓ Starry sky fluorescence IgG, C3, IgM.	• No anti GBM ab • no IC deposits in IF & EM.

GROSS : large, pale Kidney [large white K]
flea bitten (may be)

MICROSCOPY – ✓ figure.

Light MC

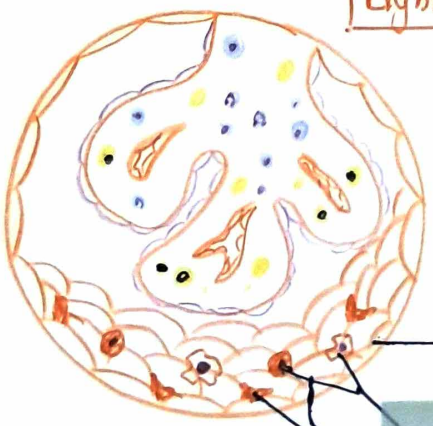

① **Glomeruli**

• **crescents** – parietal epithelial cells
WBC
Fibrin

↓

Indicate severe glomerular injury.

crescents in most of glomeruli.

parietal epithelial cells

monocyte, macrophage infiltrate

Fibrin.

② **Tubules** : tubular lumen may show RBC casts & red cells.

③ **Interstitium** : edema with few inflammatory cells.

don't draw too Many!

Electron Microscopy

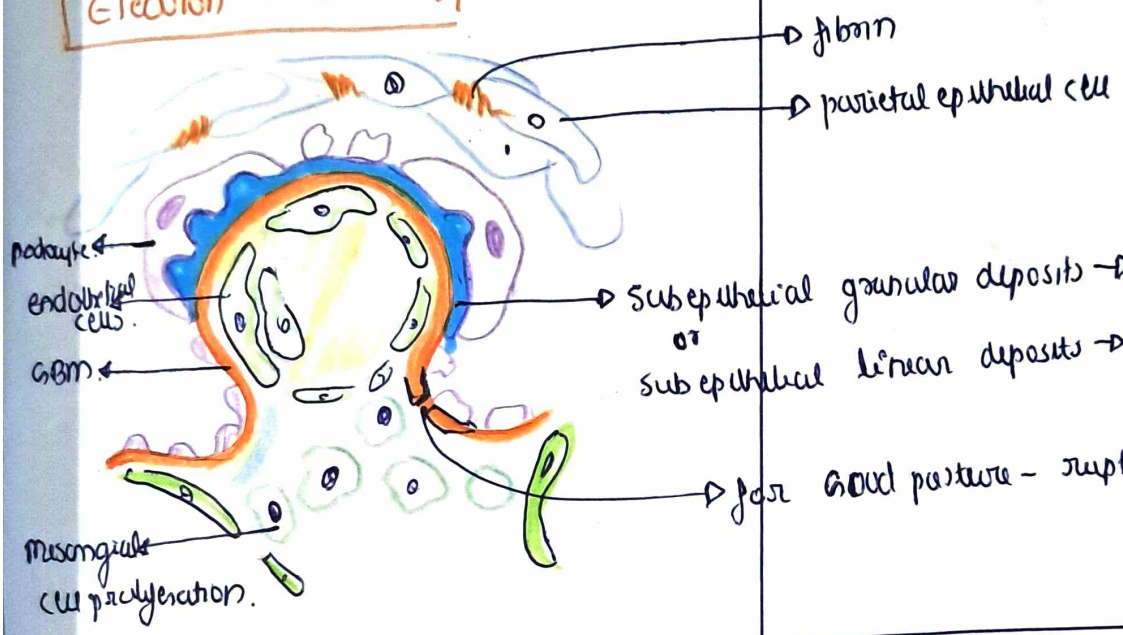

Causes of acute Nephritic Sx

I. Primary Glomerulonephritis.

1. acute Glomerulonephritis.
   - streptococcal.
   - non streptococcal.
2. Rapidly progressive GN
3. Membrano proliferative GN.
4. focus & diffuse proliferative GN
5. IgA nephropathy.

II. systemic diseases.

1. SLE
2. polyarteritis nodosa.
3. wegeners
4. HSP.
5.

Diabetic Nephropathy

- It is a microvascular complication of diabetes mellitus
  ↓ leading to.
  Chronic kidney disease.
  and is, an important cause of end-stage renal disease worldwide. (ESRD)

pathogenesis

Chronic hyperglycemia.
↓
non enzymatic glycation of proteins.
↓
Basement membrane thickening, mesangial expansion, & glomerulosclerosis.

Epidemiology

- more common in Type 2.
- → develops after years of persistant hyperglycemia.

Clinical features.

- earliest sign
  ↓
  microalbuminuria.
  (30 → 300 mg/day)
- Hypertension
- progressive decrease in GFR → ESRD.
- LFABP – marker.

Morphology

Renal lesions in Diabetes.

1. Glomerular lesions
2. Vascular lesions
3. tubular lesions
4. pyelonephritis.

Glomerular Lesions

- most common ✓

they include:

1. diffuse thickening of Glomerular capillary Basement membrane.
2. Diffuse mesangial sclerosis
3. Nodular glomerulosclerosis.
4. Insudative lesions.

① Diffuse thickening of GBM.

② Diffuse Mesangial sclerosis. → increase in PAS ⊕ mesangial matrix & cells.

③ Nodular glomerulo sclerosis → Intercapillary Glomerulosclerosis / Kimmelstiel - wilson disease.

↓

pathognomonic.

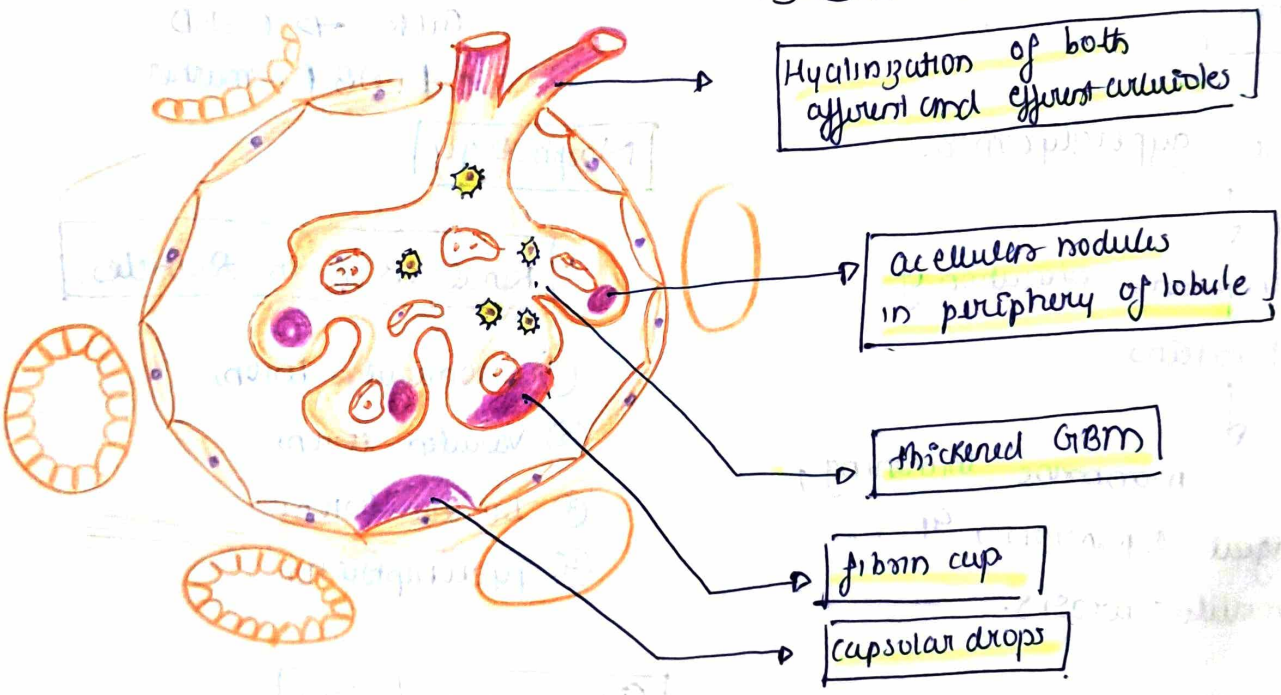

Kimmelstiel - wilson

- ovoid/spherical, laminated, PAS⊕ nodules of mesangial matrix. situated in periphery of glomerulus.
- these nodules can be surrounded by peripheral capillary loops.

Inductive lesions

① fibrin caps
↓
Subendothelial accumulation of hyaline material in / along capillary loops.

② capsular drops.
- round nodules adherent to Bowman's capsule.

Renal vascular lesions

- Hyaline arteriosclerosis.
- Renal atherosclerosis.

Pyelonephritis

- tubulo interstitial inflammation of kidneys.
- acute, chronic pyelonephritis
- necrotizing papillitis.

Tubular lesions

- Armanni - Ebstein lesions.
- tubular epithelial cells.

↓

Extensive vacuoles of glycogen

↓

Clear cytoplasm.

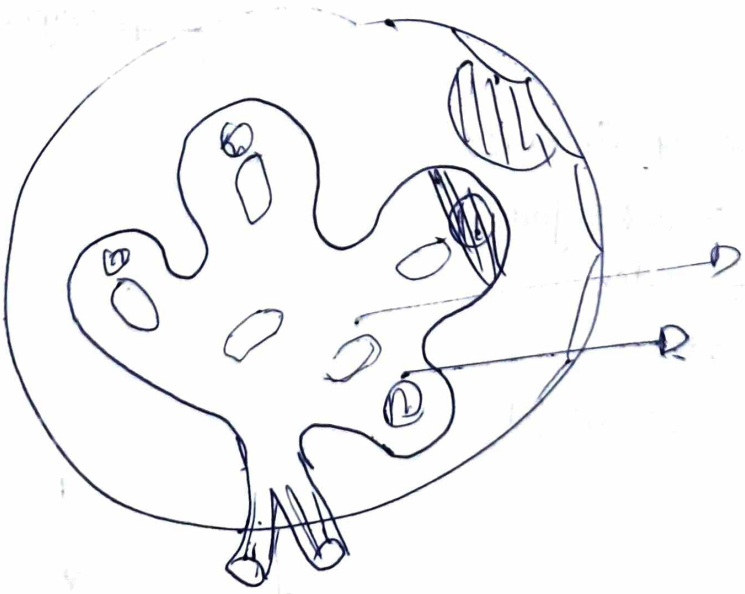

Chronic Glomerulonephritis

- chronic GN is the final stage of a variety of glomerular disease.

↓

that results in irreversible impairment of renal function.

Causes

- RPGN
- membranous GN
- membranoproliferative GN.
- FSGS.
- IgA nephropathy.
- PSGN.
- Idiopathic.

GROSS

- Kidneys are symmetrically contracted.
- Diffusely Granular cortical surface.
- capsule is adherent to cortex

Cut section : thinned cortex.

Increase in peripelvic fat.

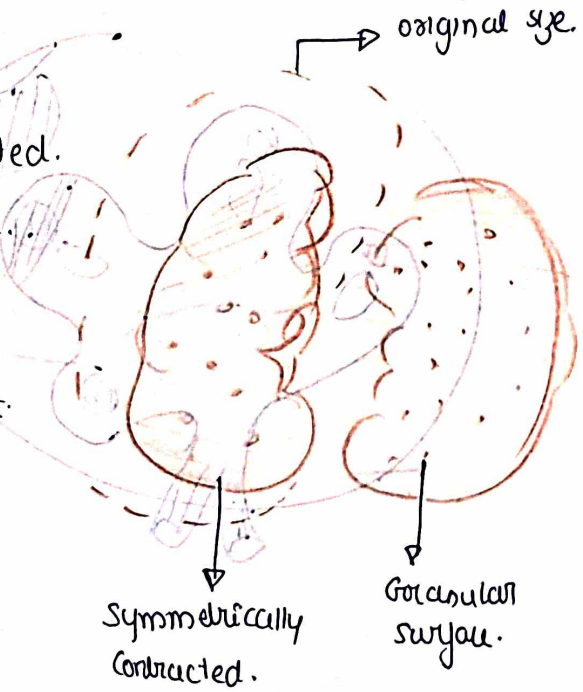

MICROSCOPY

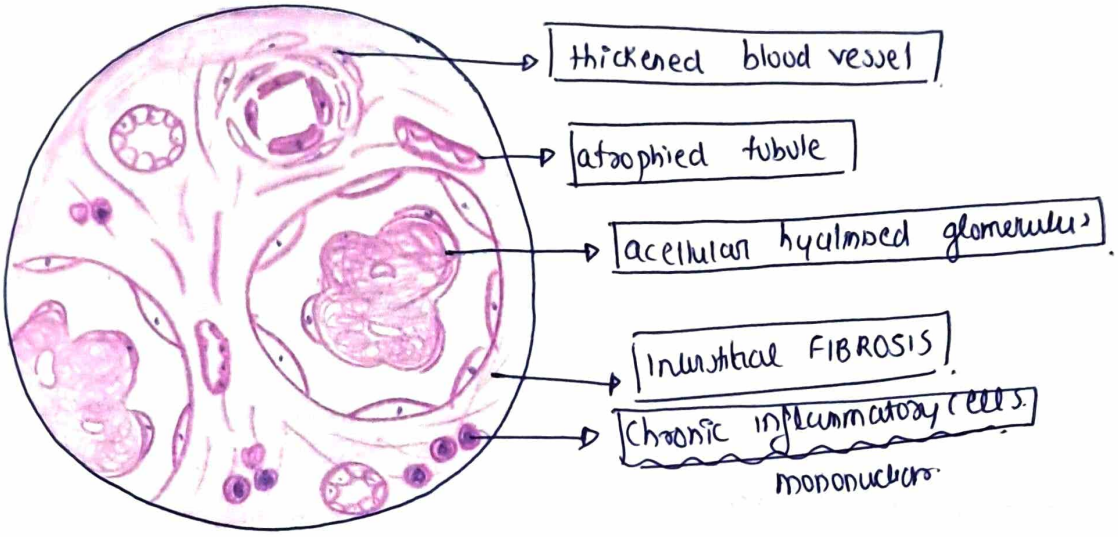

① Glomeruli : acellular, eosinophilic, PAS⊕ masses. hyalinised.

② tubules : marked atrophy, ~~tubular lumen → eosinophilic~~ casts, → Broad waxy homogenous.

③ interstitium : - fibrosis
- mononuclear WBC infiltrate

④ Vascular : arteriolar / arterial sclerosis.

Clinical features

- hypertension.
- uremia. → complications due to uremia → uremic pericarditis. uremic gastroenteritis. LV Hypertrophy.
- progressive deterioration of renal function.
- Urine → Broad waxy casts.

ofmes