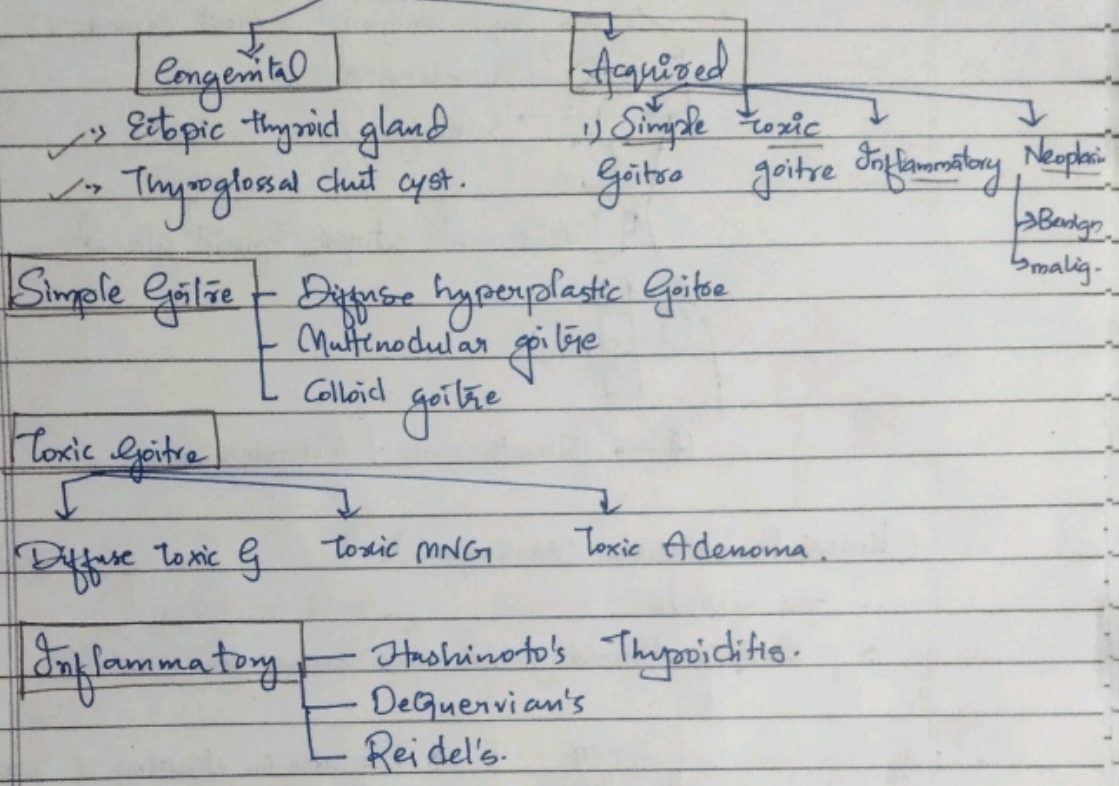
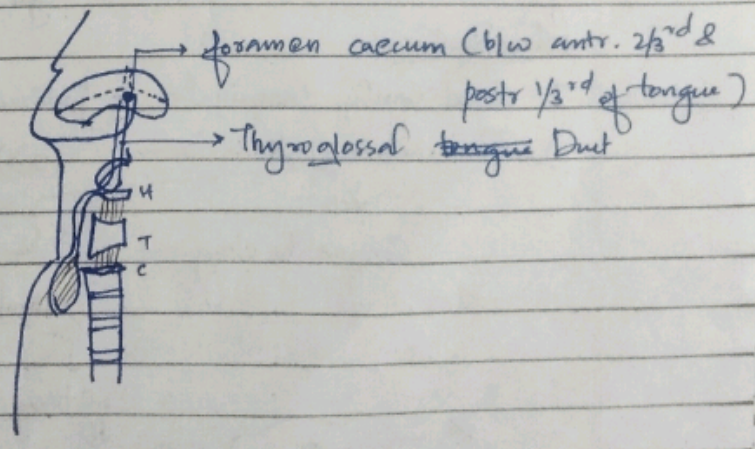


## THYROID SWELLINGS.

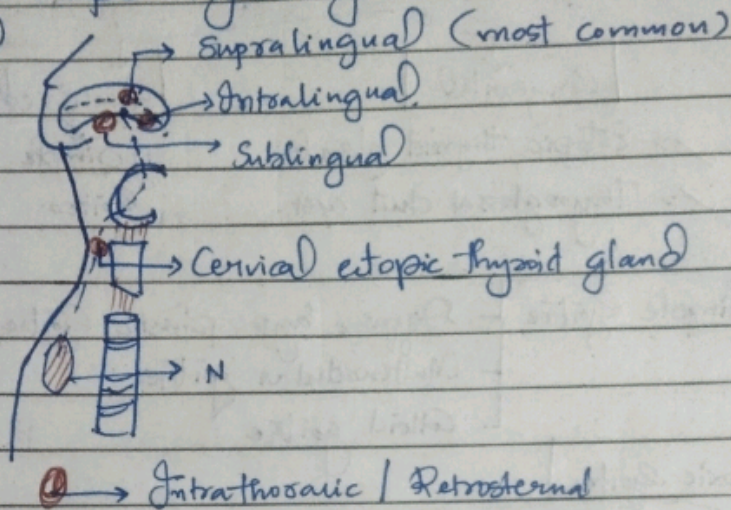


### ① ECTOPIC THYROID SWELLING.

- Abs. of thyroid gland at its normal location  
 But it will always be found at its normal Embryonic pathway.



## Location of ectopic thyroid gland.



## Clinical Presentation:- (Sublingual)

1. Age ~ 10 yrs

2. Ectopic thyroid gland

70% Solitary

30% Multiple

s/s Hypothyroidism

Euthyroid.



\* Difficulty in chewing & swallowing solid meals.

\* Difficulty in talking as well.

\* Difficulty in breathing

\* Snoring while sleeping.

\* Sign & Sympt. of hypothyroidism

## Investigations

I) Oral Cavity Examination - Indirect Laryngoscopy (IDL)

II) Radioactive Iodine Scan ( $I^{123}$ )

Confirms the diagnosis

Number of ectopic thyroid glands.

Solitary

Multiple

Suppression therapy

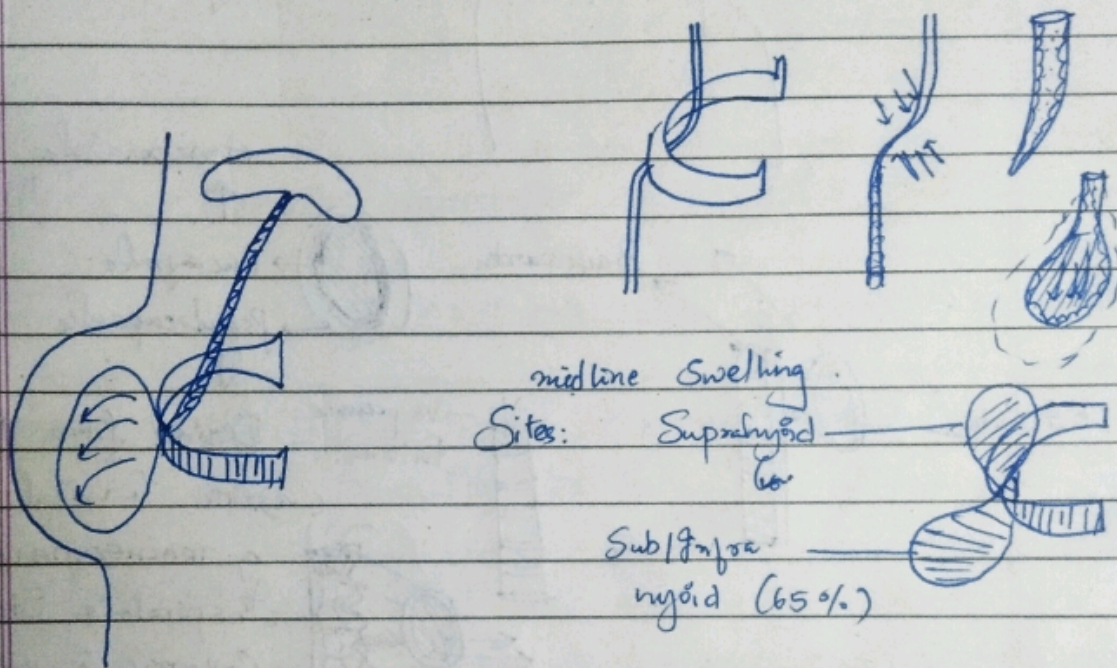
Excision

\* Thyroxine

THYROGLOSSAL DUCT CYST. - only the swelling which moves upwards with tongue protrusion

↓  
Cystic Swelling in the midline of the neck due to the remnant of Thyroglossal duct.

- TGD starts to obliterate - 5<sup>th</sup> week gestation
- TGD completely obliterates - 8<sup>th</sup> weeks.



C/F: Age ~ 20 yrs  
♀ > ♂

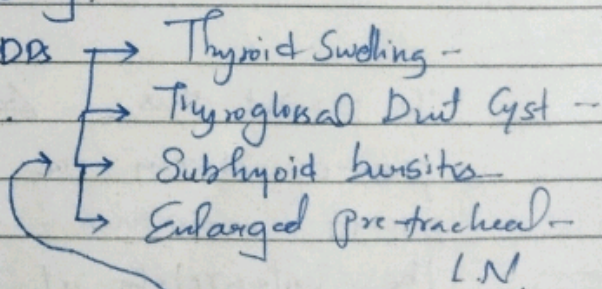
2<sup>o</sup> pr of midline neck swelling.

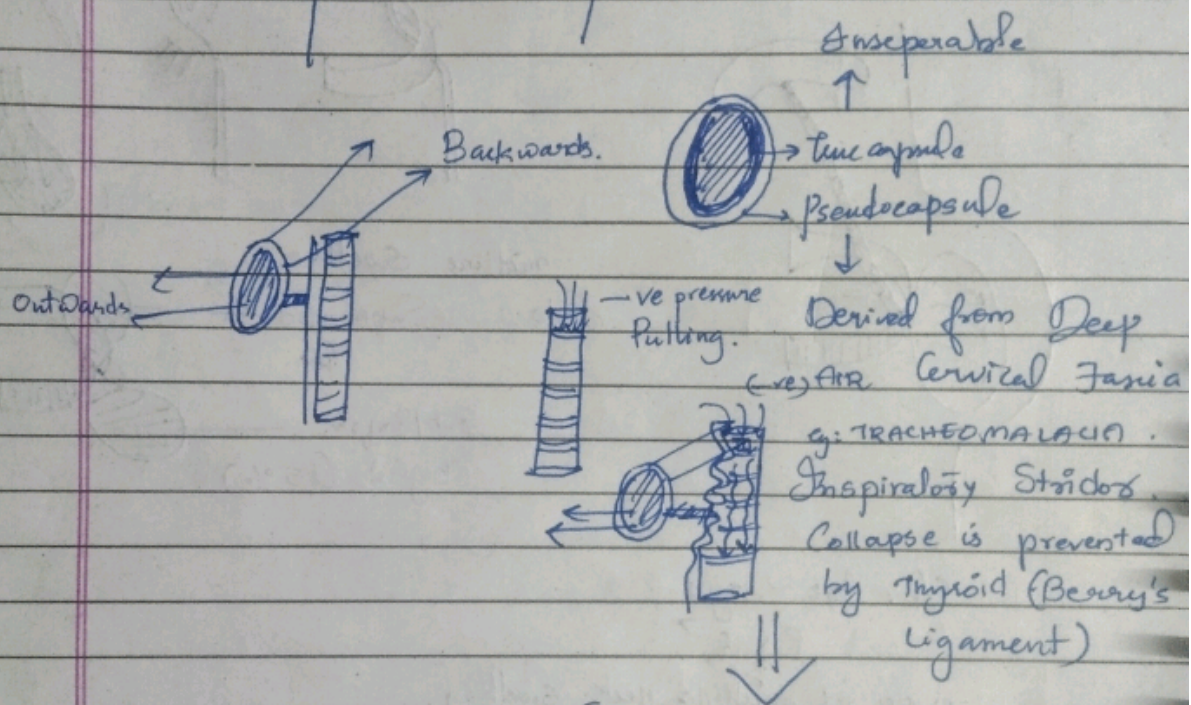
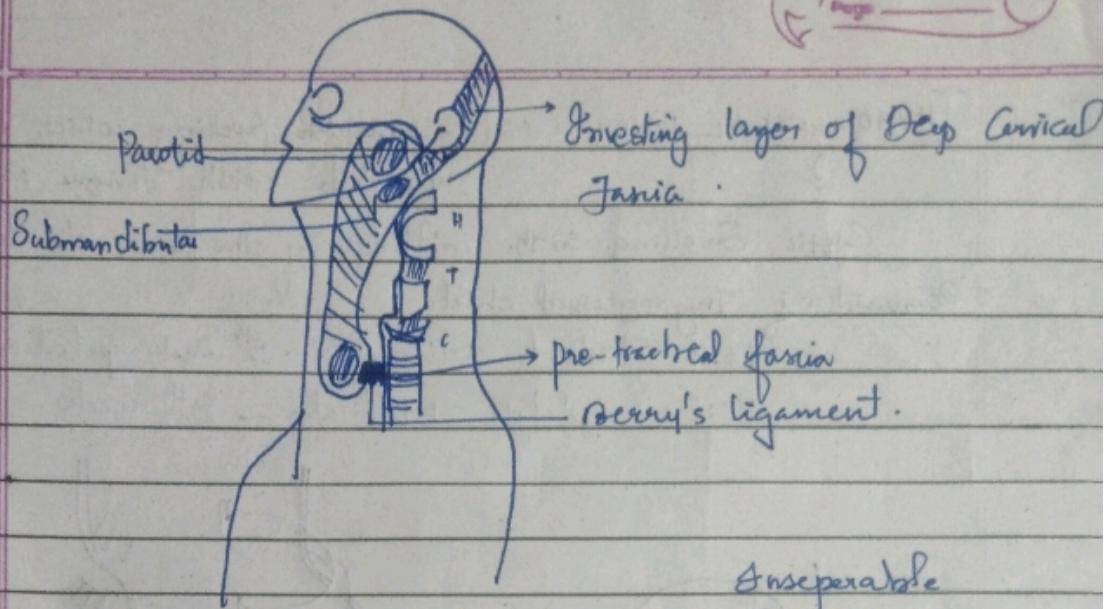
2<sup>o</sup> painless/gradually ↑ size.

Examination findings:-

- 1) Non-tender
- 2) Uniform (smooth surface), going to be soft in consistency
- 3) Move ↑ with deglutition.

↳ due to investing layer of deep cervical fascia → Berry's ligament.





To prevent this pre-operatively one should maintain the integrity of trachea thereby preventing tracheal collapse.

If the thyroid gland is removed along with Berry's ligament in long standing compression there will be post-operatively severe respiratory distress.

Berry's Sign: impalpable carotid pulse at its normal location.

(palpable - common carotid)

Surface Landmark - C6 spin

Bony-spinous process of C6 vertebra line passes through ant. border point where they intersect of sternocleidomastoid line passes through superior border of thyroid cartilage.

Berry's Aneurysm: Aneurysm of Arde of Willis.

Overall m/c site of aneurysm in the body.

Berry Picking

↳ Hand pick & remove enlarged cervical lymph nodes during Sx in Papillary CT.

INVESTIGATION: USG of Neck  
TFT

FNAC → ↑ R/F (PTC)

Mx: Surgery - Sistrunk's Operation

Remove the part of the hyoid bone adherent to TG D cyst along with cyst.

